

Traumatic Cataracts: Focus On Rosette-Shaped Cataracts

Tlemcani Younes^{1*}, Boujaada Anass¹, Robbana Lobna¹, Elmajdoubi Kamal¹ and Abdallah E Hassan¹

¹Ophthalmology B department, Faculty of Medicine, Mohammed V University Rabat, Morocco

***Corresponding Author:**

TlemcaniYounes,
Ophthalmology B department, Faculty of Medicine, Mohammed V University Rabat, Morocco.

Received Date: 23 April 2024

Accepted Date: 06 May 2024

Published Date: 13 May 2024

Citation:

TlemcaniYounes. Traumatic Cataracts: Focus On Rosette-Shaped Cataracts. Annals of Clinical and Medical Case Reports 2024.

1. Abstract

Traumatic Cataract Is a serious and common condition that mainly affects young adults and children. We report the case of a 25-year-old female patient who presented for consultation with blurred vision that had been progressively developing for over a year and in whom the clinical examination revealed a rosette-shaped cataract.

Keywords:

Subcapsular cataract; Trauma; Rosette cataract.

2. Background

The rosette-shaped cataract is a common type of cataract that can appear immediately after the trauma, most commonly blunt trauma, [1] or several months or even years later, and may remain stable without significantly altering visual acuity or progressively develop into cortico-nuclear or total forms. [2] In some cases, it can also be caused by exposure to radiation [3] or, more rarely, in diabetic patients. The purpose of this case report is to highlight the specific clinical characteristics of certain forms of traumatic cataracts, in particular rosette cataracts.

3. Case Report

We report the case of a 25-year-old patient who presented for consultation with a visual blur that had been progressively developing for 1 year. The history found that the patient had suffered eye trauma from a punch more than 4 years previously. Ophthalmological Examination Revealed Visual Acuity of 7/10ths on the right and 10/10ths on the left.

Slit-lamp examination revealed a posterior subcapsular cataract with thin blades forming a rose shape in the right eye. (Figure 1, Figure 2); Examination of the dilated fundus revealed no abnormalities. B-scan ultrasonography showed a clear vitreous cavity without structural globe anomalies. Examination of the left eye was strictly normal. Intraocular pressure on the applanation tonometer was 13 mm Hg in both eyes.

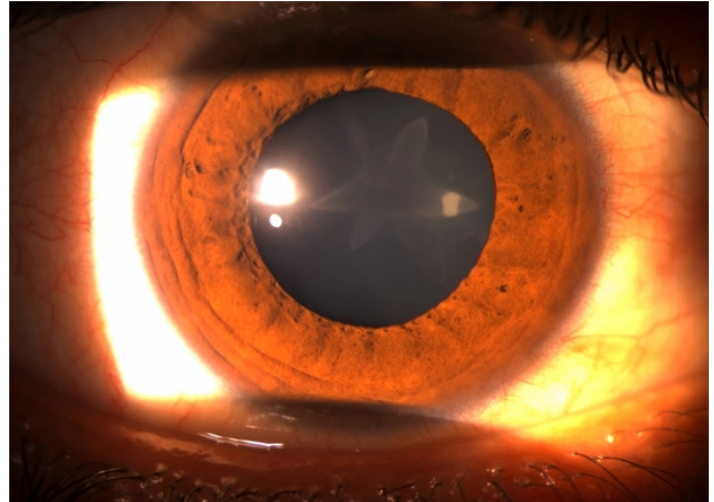


Figure 1: Diffuse illumination view of the right eye's rosette cataract



Figure 2: Retro illumination view of the right eye's rosette cataract

4. Discussion

Traumatic Cataract Is a serious and common condition that mainly affects young adults and children. It is caused by blunt or penetrating trauma, The mechanism most often incriminated is contrecoup, [4] which generates shockwaves all along the path of the traumatic impact, leading to the formation of posterior subcapsular opacification in the form of a

Annals of Clinical and Medical Case Reports

rosette or star and the prognosis depends on the associated anatomical lesions. [5] As was the case for our patient. The axial extension of these opacities can lead to a fast anteroposterior expansion, resulting in a rupture of the capsule, or even of the zonule in severe trauma. A complete ophthalmological examination is essential to detect secondary lesions resulting from trauma, including wounds, hyphema, zonular rupture, lens dislocation, angle-recession glaucoma, phacoanaphylactic uveitis, retinal or choroidal detachment, optic neuropathy or retrobulbar hemorrhage.[5] During Surgery, it is important to handle the anterior capsule gently to minimize stress on the zonules, and phaco parameters should be decreased if zonular weakness is evident. [6] The functional prognosis of Traumatic Cataract Depends Mainly on the associated lesions, underlining the importance of a meticulous clinical examination. In our patient's case, since the visual acuity has been preserved, surgery is currently being deferred, with regular monitoring of the progress of her cataract.

5. Conclusion

The rosette-shaped cataract is a specific type of cataract where the lens appears to have a series of radial spoke-like opacities. In the case of our patient, where the surgery has been deferred, it's important to closely monitor the progression of the rosette cataract. Regular follow-up examinations are crucial to assess any changes in visual acuity and their impact on daily life.

References

1. Fyodorov SN, Egorova EV, Zubareva LN. 1004 cases of traumatic cataract surgery with implantation of an intraocular lens. *J Am Intraocul Implant Soc. avr 1981;7(2):147-53.*
2. Sethi A, Ramasubramanian S. Double rosette cataract: A striking image! *Indian J Ophthalmol. janv 2019;67(1):124-5.*
3. Tasman w, Jaeger E. Traumatic cataract. *Duane's Clinical Ophthalmology. 1997;13-4.*
4. Shah MA, Shah SM, Shah SB, Patel CG, Patel UA. Morphology of traumatic cataract: does it play a role in final visual outcome? *BMJ Open. 29 juill 2011;1(1):e000060.*
5. Singh RB, Thakur S, Ichhpujani P. Traumatic rosette cataract. *BMJ Case Rep. 28 nov 2018;11(1):e227465.*
6. Okoye GS, Gurnani B. Traumatic Cataract. In: *StatPearls [Internet]. Treasure Island (FL): StatPearls Publishing; 2024.*