

# Pituitary Metastasis Of Signet-Ring Cell Carcinoma Cell Carcinoma Of The Lung With Diabetes Insipidus As The Initial Presentation:A Case Report

Wuhongli<sup>1</sup>, Lixuefeng<sup>1\*</sup>, Mengmiao<sup>2</sup>, Shangguodong<sup>3</sup>, Maqihong<sup>1</sup> and Penghuifang<sup>4</sup>

<sup>1</sup>Department of Endocrine and Metabolic Diseases, the Second Affiliated Hospital of Henan University of Science and Technology

<sup>2</sup>Department of Oncology, the Second Affiliated Hospital of Henan University of Science and Technology

<sup>3</sup>Department of Pathology, The Second Affiliated Hospital of Henan University of Science and Technology

<sup>4</sup>Endocrinology and Metabolism Center, The First Affiliated Hospital of Henan University of Science and Technology, College of Clinical Medicine, Henan University of Science and Technology; He Provincial Key Laboratory of Genetic Rare Diseases; National Clinical Medical Research Center for Metabolic Diseases Luoyang Branch 471000

## \*Corresponding author:

Lixuefeng,

Department of Endocrine and Metabolic Diseases, the Second Affiliated Hospital of Henan University of Science and Technology,

Received Date: 06 Jun 2023

Accepted Date: 06 July 2023

Published Date: 17 July 2023

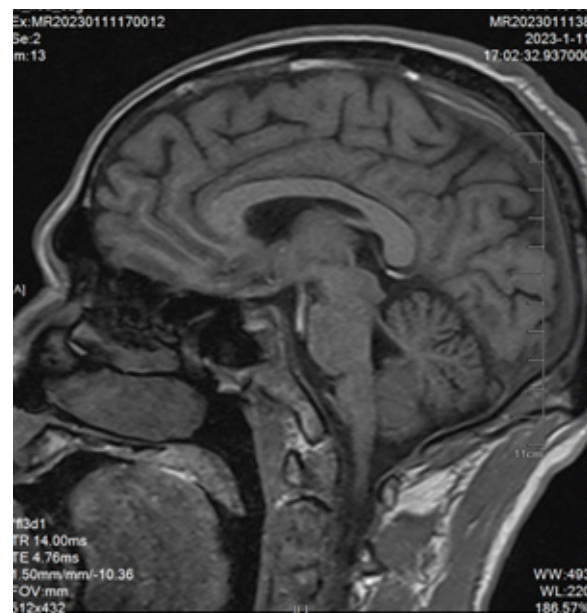
## 1. Introduction

Pituitary gland is a rare site for metastasis of malignant tumors. Pituitary metastases accounted for 0.4% of all intracranial metastases and only 1% of operative pituitary lesions [1,2]. But that number is likely to keep rising as patients with metastatic malignancies live longer. Signet ring cell carcinoma is a specific type of adenocarcinoma that occurs most commonly in the stomach and rarely in the lung [3]. signet-ring cell carcinoma of the lung is an extremely rare non-adenocarcinoma subtype, with metastasis to the pituitary gland or sellar region even rarer. Recently, 1 case of pituitary metastasis of signet-ring cell carcinoma of the lung confirmed by lung puncture pathology was admitted to our hospital, and the relevant literature was reviewed as follows.

## 2. Case Report

A 48-year-old male was admitted to our department with diabetes insipidus for 4 months due to hypopituitarism. MRI of pituitary gland was perfected to reveal saddle region lesions with isostrong signals on T1 and T2-weighted images, about 1.6cm (high diameter) × 1.2cm (anteroposterior

diameter) × 1.7cm (Hardy-Wilson grading, grade 3), accompanied by optic chiasma compression. Hormone assessment showed secondary hypothyroidism (thyrotropin, 0.944mIU/l; Free triiodothyronine, 2.54 pmol/l; Free thyroxine, 10.13 pmol/l), elevated prolactin (1282 ng/ml), hypogonadotropin (luteinizing hormone, 0.1 IU/l; Follicle-stimulating hormone, 0.1 IU/l; Total testosterone, 0.09 ng/ml), secondary hypocortisolism (corticotropin at 08:00 AM, 22.13 pg/ml; Cortisol at 8:00 AM, 52.79µg/dl). Serum osmol pressure was 286mosm /l, urine osmol pressure 312mosm /l, and 24-hour urine collection volume was 6120 ml. The clinical diagnosis was pituitary tumor and hypopituitarism. Due to poor diet, mild anemia and mild tenderness in the upper abdomen, the patient was found to have multiple solid space occupying in the liver by improved color ultrasound examination. Further improvement of the chest and abdomen CT diagnosis of the left upper hilar mass and liver multiple metastases. Histopathological and immunohistochemical examination confirmed the infiltration of signet ring tumor cells on the left lung. Immunohistochemical examination showed CK(+), TTF-1(+), Napsin A(-), CDX-2(-), CK7(+), CK20(-), SATB2(-), CK5/6(-), P40(-), CK(+), TTF-1(+), Napsin A(-), CDX-2(-), CK(+), CK5/6(-), CK19(+), CK18(+). On 13 January 2023, he was given «Meigen 0.05mg/time, twice/day», «Levothyroxine sodium (Unimethylle) 50µg/ time, once/day», «Prednisone acetate orally (early 20mg/ time, late 10mg/ time)».

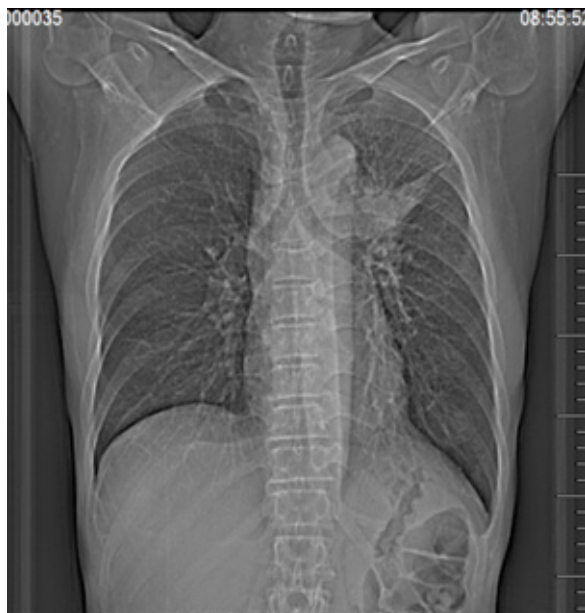

**Figure 1:** pituitary MRI in patients with pituitary have a 1.6 cm (diameter) \* 1.2 cm (diameter) before and after \* 1.7 cm (diameter) around the lump, a “waist” growth, pituitary stalk display is not clear, the optic chiasma

# Annals of Clinical and Medical Case Reports

slightly elevate, bilateral cavernous sinus area is local lesion.

After the MDT (neurosurgery, thoracic surgery, oncology, endocrinology) of the expert group, chemotherapy was started on January 18, 2023. The chemotherapy regimen was carboplatin AUC 5 d1 + pemetrexed 500 mg/m<sup>2</sup>d1 Q21d+ bevacizumab 15mg/kg d1 Q21d. After 2 cycles of chemotherapy, the symptoms of dry mouth and thirst were better than before, and the condition was stable by imaging examination. A large amount of pleural effusion was found during the third cycle of chemotherapy, and imaging examination again suggested multiple bone metastases. The modified chemotherapy regimen was (cisplatin 80mg/m<sup>2</sup>d1 Q21d+ Carrilizumab 200mg d1+ bevacizumab 7.5mg/kg d1 Q21d+ albumin-binding paclitaxel 100 mg/m<sup>2</sup>d1 Q8d) antivasular combined chemotherapy. Pleural catheter drainage and injection of recombinant human endostatin 45mg intrathoracic lavage solution were performed. At the fourth cycle, imaging examination showed no significant changes in the lesions of the patient, but the patient's basic condition was poor at present. The treatment regimen was adjusted again as (antirotinib 12mg/time, once/day + tirelizumab 200mg d1+ albumin-binding paclitaxel 100 mg/m<sup>2</sup>d1 Q8d).



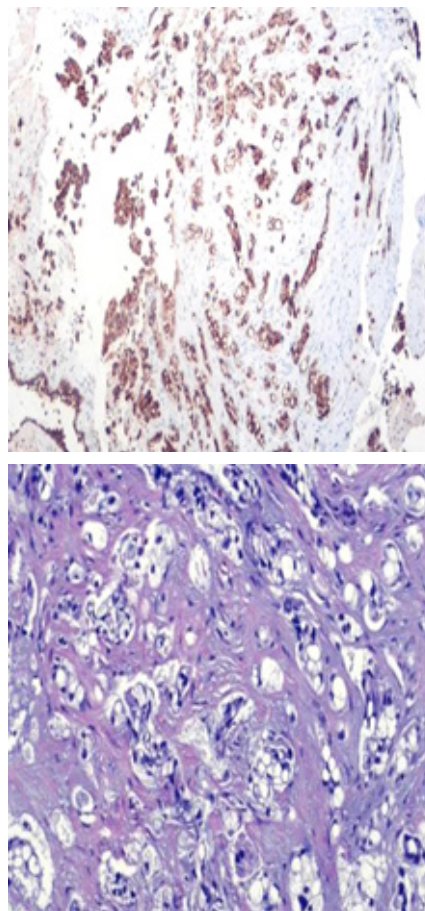
**Figure 2:** Plain CT scan of the chest showed a 4.3cm×2.6cm mass in the hilar area of the left upper lobe, and bronchial occlusion in the posterior and anterior segments of the left upper lobe.

### 3. Discussion

Pituitary metastases only accounted for 1% ~ 2% of all sellar areas [4], and were mostly found in advanced patients with distant metastasis of malignant tumors. In a large autopsy, pituitary metastases were found to account for about 1% to 3.6% of all malignancies in the body [5]. In 1857 Benjamin reported the first case of a patient with malignant melanoma in which pituitary metastasis was found in autopsy [6]. Since then, with the progress of imaging and tumor treatment, the life span of patients with malignant tumors has been gradually extended, and more and more cases

of pituitary metastasis of malignant tumors have been reported.

The clinical manifestations of pituitary metastasis are similar to pituitary adenoma, including visual field defect, hypohypopituitary function, diabetes insipidus, retroorbital eye pain, ocular paralysis, etc.[7]. Diabetes insipidus is the most common symptom and its main cause is due to damage to the posterior pituitary [8]. Hypothyroidism, hypoadrenal function and hyperprolactinemia are the three major manifestations of anterior pituitary involvement. Malignant tumors with pituitary metastasis are mostly located outside the skull, such as lung cancer, breast cancer, kidney cancer, prostate cancer, thyroid cancer, leukemia, etc [9]. Essadi et al reported pituitary metastasis of rhabdomyosarcoma [10]. Tanaka et al reported a case of hypopituitarism caused by metastasis of hepatocellular carcinoma to the pituitary [11]. The patient died of hypovolemic shock despite active hormone replacement therapy. Liu et al. reported a case of pituitary metastasis of choriocarcinoma [12], Wang et al reported a rare case of mantle cell lymphoma with pituitary metastasis [13] Merchant et al. reported one case of primary tonsil squamous cell carcinoma metastasizing to pituitary gland [14]. It can be inferred that pituitary metastasis may occur in various types of malignant tumors. We are the first to report pituitary metastasis from primary signet ring cell carcinoma of the lung.



**Figure 3:** Histopathological manifestations: on the left lung tumor cells infiltrating signet ring samples, immunohistochemical examination for CK (+), (+), the vera.ttf - 1 Napsin A (-), CDX - 2 (-), CK7 (+), CK20 (-),

# Annals of Clinical and Medical Case Reports

SATB2 (-), CK5/6 (-), P40 (-), CK19 were (+), CK18(+)(hematoxylin and eosin staining, magnification×200).

Signet ring cell carcinoma (SRCC) is a special type of mucus-secreting adenocarcinoma derived from undifferentiated stem cells of mucous membrane propria [15]. It is characterized by poor differentiation, diffuse infiltration, rapid growth and difficult early diagnosis. Signet ring cell carcinoma usually occurs in the gastrointestinal tract, prostate or breast. About 3.1% of these signet-ring cell carcinomas may originate in the lung [16]. Both signet ring cell carcinoma of the lung and pituitary metastases suggest a poor prognosis. Fassett et al conducted a retrospective analysis of 36 patients with pituitary metastasis, and found that the average survival time of patients was only 6 months [17]. And the more severe the disease, the shorter the survival. A systematic review of 657 pituitary metastases by Sam Ng et al showed a median PM survival of only 14 months [18]. The treatment of pituitary metastases should vary according to the tumor type. It usually includes surgery, postoperative gamma knife therapy, radiotherapy, chemotherapy, hormone replacement therapy, etc [19-21]. Despite the importance of surgery for symptom relief, there was no significant difference in overall survival between surgical and non-surgical patients [22]. Gamma knife is a stereoscopic radiotherapy method that has been gradually applied to patients with pituitary metastatic tumor. The treatment is well tolerated and the incidence of complications is small. It is an effective, safe and non-invasive means to improve the symptoms of patients with pituitary metastasis [23]. Although adjuvant chemotherapy and immunotherapy after diagnosis of pituitary metastatic tumor can prolong the survival cycle of patients, the treatment case reports are limited at present, and the therapeutic effect is still unclear. According to the patient's condition, hormone replacement, adjuvant chemotherapy and immunotherapy are finally selected, so far the effect is not ideal.

**Table 1:** Examination results of endocrine and tumor markers on admission

Laboratory test	Patient's value	Reference range
GH	6.48	0.06-5.0
Cortisol[ug/dl]	52.79	72.6-322.8
ACTH[pg/ml]	22.13	6-40
PRL [mIU/L]	1282	86-324
FSH[mIU/mL]	0.1	1.7-8.6
LH[mIU/mL]	0.1	1.5-12.4
T[nmol/l]	0.09	8.64-29.0
E[pmol/l]	26.62	11.3-43.2
FT3[pmol/L]	2.54	3.1-6.8
FT4[pmol/L]	10.13	12-22
TSH[μIU/mL]	0.944	0.27-4.2

Morning sample

GH, growth hormone; ACTH, adrenocorticotropin; PRL, prolactin; FSH, follicle-stimulating hormone; LH, luteinizing hormone; T, testosterone; E, estrogen; FT3, free triiodothyronine; FT4, free thyroxine; TSH, thyroid stimulating hormone;

Our patient is the first reported case of metastasis from signet-ring cell carcinoma of the lung to the pituitary gland. We have learned from previous cases that the disease has a high degree of malignancy. At present, the patient continues regular chemotherapy and adjusts chemotherapy regimen several times, but the disease still progresses continuously. The clinical and prognostic observation of this patient will provide experience for the diagnosis and treatment of this disease in the future. It is hoped that better treatments will be available to these patients in the future.

## References:

- Habu M, Tokimura H, Hirano H, et al: Pituitary metastases: current practice in Japan. *J Neurosurg* 123:998-1007, 2015
- He W, Chen F, Dalm B, et al: Metastatic involvement of the pituitary gland: a systematic review with pooled individual patient data analysis. *Pituitary* 18:159-68, 2015
- Kish JK, Ro JY, Ayala AG, et al: Primary mucinous adenocarcinoma of the lung with signet-ring cells: a histochemical comparison with signet-ring cell carcinomas of other sites. *Hum Pathol* 20:1097-102, 1989
- Gsponer J, De Tribolet N, Deruaz JP, et al: Diagnosis, treatment, and outcome of pituitary tumors and other abnormal intrasellar masses. Retrospective analysis of 353 patients. *Medicine (Baltimore)* 78:236-69, 1999
- Tanaka T, Hiramatsu K, Nosaka T, et al: Pituitary metastasis of hepatocellular carcinoma presenting with panhypopituitarism: a case report. *BMC Cancer* 15:863, 2015
- Chiang MF, Brock M, Patt S: Pituitary metastases. *Neurochirurgia (Stuttg)* 33:127-31, 1990
- Shimon I: Metastatic Spread to the Pituitary. *Neuroendocrinology* 110:805-808, 2020
- Houck WA, Olson KB, Horton J: Clinical features of tumor metastasis to the pituitary. *Cancer* 26:656-9, 1970
- Henry A, Nugent A, Wallace IR, et al: Pituitary metastasis: a clinical overview. *Ulster Med J* 90:146-150, 2021
- Ismail E, Issam L, Hamid M: Pituitary metastasis of rhabdomyosarcoma: a case report and review of the literature. *J Med Case Rep* 8:144, 2014
- Tanaka T, Hiramatsu K, Nosaka T, et al: Pituitary metastasis of hepatocellular carcinoma presenting with panhypopituitarism: a case report. *BMC Cancer* 15:863, 2015
- Liu H, Xiao YD, Peng SP, et al: Pituitary metastasis of choriocarcinoma: A case report. *Oncol Lett* 11:1517-1520, 2016
- Wang A, Carberry N, Solli E, et al: Metastatic Mantle Cell Lymphoma to the Pituitary Gland: Case Report and Literature Review. *Case Rep Oncol* 9:25-32, 2016
- Merchant H, Rye DS, Smith JA: Isolated pituitary fossa metastasis

# Annals of Clinical and Medical Case Reports

- from a primary tonsillar squamous cell carcinoma: case report. *J Laryngol Otol* 134:369-371, 2020
15. Kish JK, Ro JY, Ayala AG, et al: Primary mucinous adenocarcinoma of the lung with signet-ring cells: a histochemical comparison with signet-ring cell carcinomas of other sites. *Hum Pathol* 20:1097-102, 1989
  16. Cai Y, Xie Y, Xiong Y, et al: Clinicopathological characteristics and survival in lung signet ring cell carcinoma: a population-based study. *Bosn J Basic Med Sci* 21:752-759, 2021
  17. Fassett DR, Couldwell WT: Metastases to the pituitary gland. *Neurosurg Focus* 16:E8, 2004
  18. Ng S, Fomekong F, Delabar V, et al: Current status and treatment modalities in metastases to the pituitary: a systematic review. *J Neurooncol* 146:219-227, 2020
  19. Javanbakht A, D'Apuzzo M, Badie B, et al: Pituitary metastasis: a rare condition. *Endocr Connect* 7:1049-57, 2018
  20. Zoli M, Mazzatenta D, Faustini-Fustini M, et al: Pituitary metastases: role of surgery. *World Neurosurg* 79:327-30, 2013
  21. Lithgow K, Siqueira I, Senthil L, et al: Pituitary metastases: presentation and outcomes from a pituitary center over the last decade. *Pituitary* 23:258-265, 2020
  22. Zoli M, Mazzatenta D, Faustini-Fustini M, et al: Pituitary metastases: role of surgery. *World Neurosurg* 79:327-30, 2013
  23. Piedra MP, Brown PD, Carpenter PC, et al: Resolution of diabetes insipidus following gamma knife surgery for a solitary metastasis to the pituitary stalk. Case report. *J Neurosurg* 101:1053-6, 2004