

Sub-Dural Hematoma and COVID-19 Infection: Re-Bleeding Following Anti-Coagulation

Sandio A^{1*}, Casimir F², Figuim B³, Serge N⁴, Batamack Y⁵, Kamto T⁵, Aboaba AO⁶, Tsafack NL⁵, Asare S¹, Cadet P¹, Tynes D¹ and Paul DVD³

¹Department of Neurosurgery, Wayne State University, Detroit Medical Center, USA

²Department of Neurosurgery CURY, Wayne State University, USA

³Department of Neurosurgery, University of Yaounde, USA

⁴Department of Anesthesiology & Reanimation, CURY, University of Yaounde, USA

⁵Department of Neurosurgery and HCY, Wayne State University, USA

⁶Department of Internal Medicine, Avalon University, USA

*Corresponding author:

Aubin Sandio,
Department of Neurosurgery, Wayne State
University, Detroit Medical Center, 4201 St
Antoine, MI 48201, USA,
E-mail: asandio@med.wayne.edu

Received: 01 Mar 2022

Accepted: 15 Mar 2022

Published: 21 Mar 2022

J Short Name: ACMCR

Copyright:

©2022 Sandio A. This is an open access article distributed under the terms of the Creative Commons Attribution License, which permits unrestricted use, distribution, and build upon your work non-commercially.

Citation:

Sandio A, Sub-Dural Hematoma and COVID-19 Infection: Re-Bleeding Following Anti-Coagulation. *Ann Clin Med Case Rep.* 2022; V8(15): 1-4

Keywords:

Anti-Coagulation; COVID-19; Hypercoagulability

1. Abstract

Chronic subdural hematoma generally occurs in elderly patients. Anti-coagulation is also a frequent risk factor for this disease. The objective of this report was to present the rare case of a right hemispheric subdural hematoma associated with a COVID-19 lung infection in an 81 years old female patient, both diagnoses confirmed with imaging and biological work-up. On admission, she presented with an altered general state as well altered state of consciousness, chest pain and left side motor deficit. The management of the subdural hematoma was surgical while the COVID-19 pneumonia was managed using a medical protocol which included curative anticoagulation. The post-operative course was marked by re-bleeding of the subdural hematoma. This case report thus brings out the ambiguity regarding the possible association of COVID-19 infection and chronic subdural hematoma on one hand, and the risk-benefit effect of using anticoagulants in COVID-19 patients presenting a high risk of bleeding, on the other hand [1-5].

2. Case Presentation

We report the case of an 81 years old woman presenting with sub-acute subdural hematoma associated with COVID-19 pneumonia. It was a female married Cameroonian housewife; hypertensive for over 3 years, followed up but not compliant to treatment. She had an ischemic stroke 2 years ago with no sequelae but not documented. She is also known to have a cardiopathy with atrial fibrillation.

She was brought to the Yaoundé Emergency Centre (YEC) for behavioral changes and left side motor deficit of progressive evolution over 2 weeks prior to consultation [6-10]. There was no notion of head trauma. Otherwise, she had chest pains.

Physical examination revealed:

- Altered general state with asthenia;
- Altered state of consciousness with a GCS of 13/15;
- Left hemiparesis at 3/5;
- Lung and heart exams were unremarkable;
- Vital parameters were within normal limits;
- The rest of physical examination was normal.

3. Introduction

With regards to this clinical picture of a sub-acute right hemispheric subdural hematoma with mass effect and altered conscious state, as well as a COVID-19 pneumonia, the management strategy developed was first to treat the subdural hematoma, then the COVID-19 infection. A trepanation was done with washing and drainage of the subdural hematoma under local anesthesia and sedation. She was installed in the supine position, head turned towards the left. A 5cm linear right frontal-parietal incision was done following the superior temporal line and a borehole was created behind the coronal suture. Per operative finding was a dark fluid with an “engine oil” aspect mixed with some blood clots.

Abundant washing of the subdural space was done using isotonic normal saline and closure was done in two planes after placing a non-aspirate redon drain. The intervention was well tolerated. Post-operative treatment comprised of analgesics and prophylactic antibiotics at meningeal doses. The patient was then transferred to the COVID-19 treatment unit of the Yaoundé Central Hospital (YCH) [11-13]. On Admission, she complained of fatigue and had an acute respiratory distress syndrome. She was placed on a management protocol for COVID-19 comprising; high concentration mask oxygen therapy, Azithromycin, Amoxicillin-clavulanic acid, Vitamin C, Vitamin D, Zinc, a bolus of Methylprednisolone, curative dosage of Enoxaparin. The evolution a few days later was marked by the progressive improvement in the state of consciousness, as well as regression of the left hemiparesis and respiratory difficulties notably with amelioration of the oxygen saturation leading to the withdrawal of oxygen on post-operative day 8. A control COVID-19 rapid diagnostic test was negative. On post-operative day 10, the patient presented with a rapidly progressive alteration in her state of consciousness within about 12hours with her GCS moving from 13 to 11/15. A control brain CT-scan done (Figure 3) showed a bilateral pan hemispheric subdural hygroma, marked at the right with re-bleeding at the site of trepanation, without mass effect to the adjacent parenchyma. Management was conservative with Tranexamic acid, Etamsylate, Vitamin K, Methylprednisolone and Enoxaparin at prophylactic doses. The evolution 4days later was favorable with amelioration of consciousness with a GCS of 14/15. The patient was discharged on post-operative day 18, and during the follow up two weeks later, she had a good

general state, normal state of consciousness and an improvement in muscular force of the left side.

4. Discussion

It is the rare case of a female 81years old hypertensive patient, non-compliant to treatment, also having a cardiopathy with atrial fibrillation. She presented with a sub-acute subdural hematoma with mass effects associated with COVID-19 pneumonia. The hematoma was treated with surgery and pneumonia treated at a specialized COVID-19 treatment center. The anticoagulation at curative doses administered in the treatment plan would have been a risk factor for the occurrence of re-bleeding at the hematoma site in the post-operative period (Figure 1).

Administration of a short course pro-thrombotic treatment protocol associated with corticosteroids led to the control of the re-bleeding and amelioration of the neurological condition of the patient [14-17].

The doses of anticoagulants to be administered for prophylaxis in the treatment plan of moderate to severe forms of COVID-19 infections has to follow a rigorous evaluation of the risk of bleeding in patients. This also has to take into consideration the clinical state of the patient, the past history and comorbidities, especially intracranial hematoma.

Moreover, the cause and effect relationship between COVID-19 infection and the occurrence of spontaneous subdural hematoma in our patient could be the hypothesis and point of interest for further research (Figure 2 and 3).

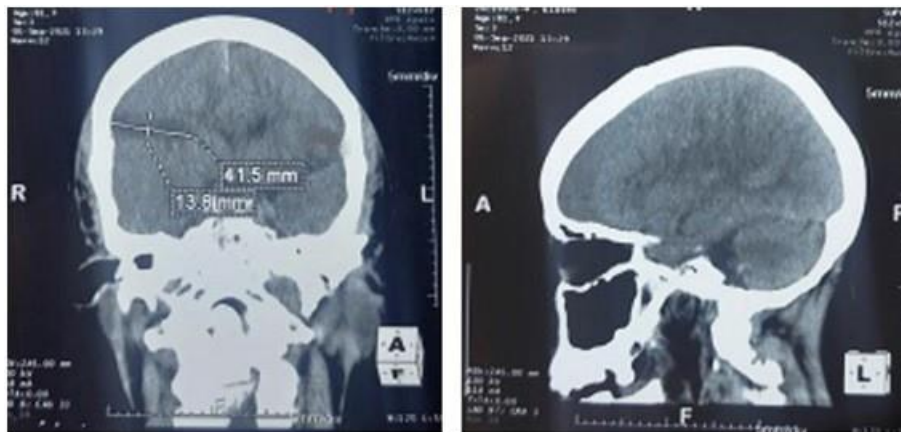


Figure 1: Brain CT-scan images revealing a sub-acute right frontal-temporo-parietal subdural hematoma with mass effect on midline structures.

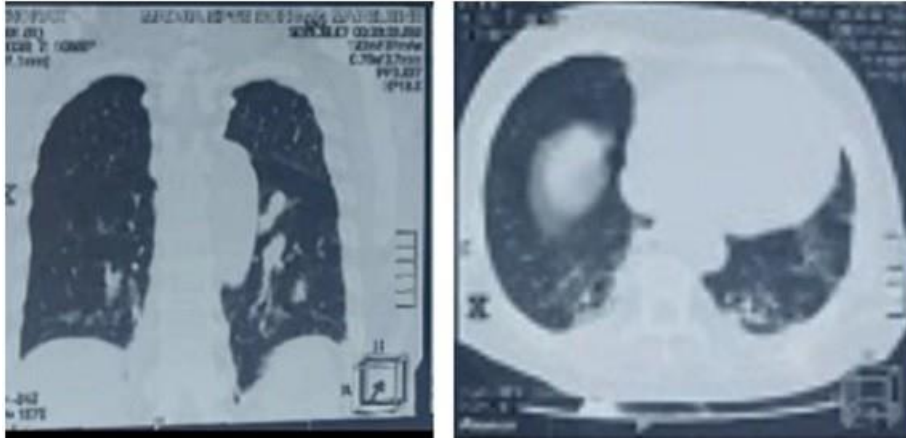


Figure 2: Images of a chest CT scan showing nodular opaque lesion of multiple locations with a diffuse frosted glass appearance.

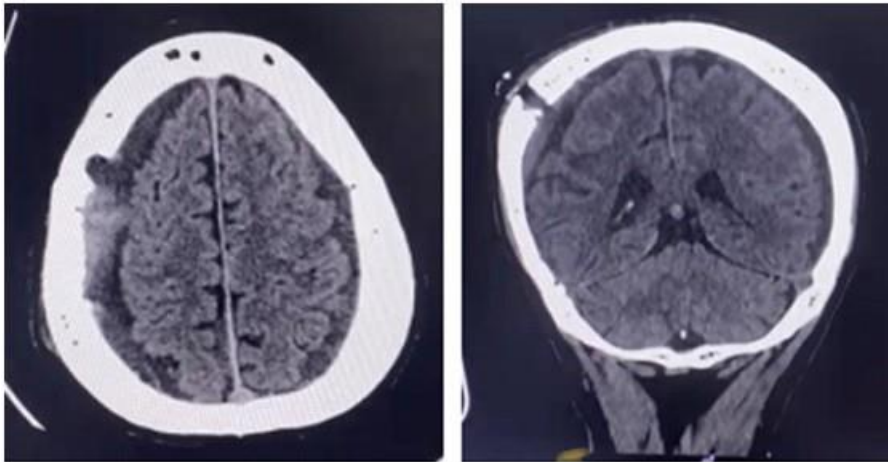


Figure 3: Control brain CT-scan images showing bilateral pan hemispheric subdural hematoma marked at the right, with re-bleeding at the site of trepanation. No mass effect on adjacent parenchyma.

5. Conclusion

The hypercoagulability of blood and thrombo-embolic events observed in patients with COVID-19 infections justified the systematic empiric use of anticoagulants in the management of these patients generally. Considering the fact that our patient presented with a severe form of COVID-19, using curative doses of anticoagulation seemed justified. However, the probable contribution of this anticoagulation to the re-bleeding of the subdural hematoma brings to light the necessity of a judicious evaluation of the risk-benefit effects as well as a consideration of the appropriate dosage before initiating an anti-thrombotic protocol in the treatment of COVID-19.

References

1. Scott M. Spontaneous Non traumatic Subdural Hematomas. *JAMA*. 1949; 141: 596–602.
2. Fogelholm R, Heiskanen O, Waltimo O. Influence of Patient's Age on Symptoms, Signs, and Thickness of Hematoma. *J Neurosurg*. 1975; 42: 43-6.
3. Samba Sivan M. An Overview of Chronic Subdural Hematoma: Experience with 2300 Cases. *SurgNeurol*. 1997; 47: 418-22.
4. Liu W, Bakker NA, Groen RJ. Chronic subdural hematoma: a systematic review and meta-analysis of surgical procedures. *J Neurosurg*. 2014; 121: 665–673.
5. Wakai S, Hashimoto K, Watanabe N, Inoh S, Ochiai C, Nagai M. Efficacy of Closed-System Drainage in Treating Chronic Subdural Hematoma: A Prospective Comparative Study. *Neurosurgery*. 1990; 26: 771-3.
6. Wintzen AR, Tijssen JGP. Subdural Hematoma and Oral Anticoagulation Therapy. *Ann Neurol*. 1982; 39: 69-72
7. Lind CR, Lind CJ, Mee EW. Reduction in the number of repeated operations for the treatment of subacute and chronic subdural hematomas by placement of subdural drains. *J Neurosurg*. 2003; 99: 44-6.
8. Markwalder T-M, Steinsiepe KF, Rohner M, Reichenbach W, Markwalder H. The Course of Chronic Subdural Hematomas After Burr-Hole Craniostomy and Closed-System Drainage. *J Neurosurg*. 1981; 55: 390-3.
9. Kawamata T, Takeshita M, Kubo O, Izawa M, Kagawa M, Takakura K. Management of Intracranial Hemorrhage Associated with Anticoagulant Therapy. *SurgNeurol*. 1995; 44: 438-43.
10. Li Y, Li M, Wang M. Acute cerebrovascular disease following COVID-19: a single center, retrospective, observational study.

Stroke Vasc Neurol. 2020 5: 279-84.

11. Xu Z, Shi L, Wang Y, Zhang J, Huang L, Zhang C, et al. Pathological findings of COVID-19 associated with acute respiratory distress syndrome. *Lancet Respir. Med.* 2020; 8: 420-2.
12. Middeldorp S, Coppens M, van Haaps TF. Incidence of venous thromboembolism in hospitalized patients with COVID-19. *J Thromb Haemost.* 2020; 00:1-8.
13. Poissy J, Goutay J, Caplan M. Pulmonary embolism in patients with COVID-19: awareness of an increases prevalence. *Circulation.* 2020; 142: 184-6.
14. Klok FA, Kruip MJHA, van der Meer NJM. Incidence of thrombotic complications in critically ill ICU patients with COVID-19. *Thromb Res.* 2020; 191: 145-7.
15. Llitjos JF, Leclerc M, Chochois C. High incidence of venous thromboembolic events in anticoagulated severe COVID-19 patients. *J Thromb Haemost.* 2020; 18: 1743-6.
16. Bikdeli B, Madhavan MV, Jimenez D. COVID-19 and Thrombotic or thromboembolic disease: implications for prevention, antithrombotic therapy, and follow-up: JACC state-of-the-art review. *J Am Coll Cardiol.* 2020; 75: 2950-73.
17. Helms J, Tacquard C, Severac F, Leonard-Lorant I, Ohana M. High risk of thrombosis in patients in severe SARS-CoV-2 infection: a multicenter prospective cohort study. *Intensive Care Med.* 2020.