

Mandibular Localizations of Ewing Sarcomas in Children: A Rare Presentation

Mbarki I*, Touimi SH, Elmajjaoui S, Kebdani T, Elkacemi H and Benjaafar N

Department of Radiotherapy, National Institute of Oncology, Mohammed V University, Rabat, Morocco

*Corresponding author:

Imane Mbarki,
Department of Radiation Oncology, National
Institute of Oncology, Mohammed V University,
Rabat, Morocco,
E-mail: imanemb25@gmail.com

Received: 06 Aug 2021

Accepted: 23 Aug 2021

Published: 31 Aug 2021

Copyright:

©2021 Mbarki I. This is an open access article distributed under the terms of the Creative Commons Attribution License, which permits unrestricted use, distribution, and build upon your work non-commercially.

Citation:

Mbarki I, Mandibular Localizations of Ewing Sarcomas in Children: A Rare Presentation. Ann Clin Med Case Rep. 2021; V7(6): 1-5

Keywords:

Ewing's Sarcoma; Mandible; Neoplasm; Child; Systemic Therapy; Local Therapy

1. Abstract

Ewing's Sarcoma (ES) is a solid tumor of bone and soft tissue, affecting mainly adolescent and young adults. It is the second most common primary bone tumor in childhood and the most lethal bone tumor. ES is more common in the axial skeleton, head and neck localization is extremely rare (2 to 4%). The purpose of this article is to discuss the case of a young patient diagnosed with mandibular Ewing's sarcoma and highlight the importance of early diagnosis.

2. Introduction

ES a rare malignant neuro-ecto-dermal tumor. It accounts for 4 to 10% of all types of bone cancer, with a predilection for long bones and pelvis [1, 2]. Facial bones are affected in 2 to 4% of cases with nonspecific symptoms. SE affects adolescents and young adults and is uncommon before 8 years and after 25 years [3]. The reported case is that of a young patient with mandibular Ewing sarcoma having benefited from multidisciplinary treatment, with an overall survival of 4 years without local or distant recurrence.

3. Case Presentation

This is a young 14-year-old patient, with no notable history, referred by her dental surgeon for a left mandibular swelling evolving for 2 months. The clinical examination revealing an expansive swelling of the left mandibular region, associated with left angulo-mandibular lymphadenopathy of about 3 cm. The intraoral examination shows a mass not invading the dental structures, the overlying mucosa was slightly erythematous without ulceration. On palpation, the tumoral masse was hard, firm, painless and with-

out any sign of inflammation. The mouth opening was normal.

A computed tomography (CT) scan with three-dimensional CT of the facial massif revealed the presence of a manifestly malignant lesion process of the left horizontal branch of the mandible (Figure 1) associated with a left Angulo-mandibular lymphadenopathy of about 4 cm (Figure 2), may be compatible with Ewing's sarcoma or osteosarcoma.

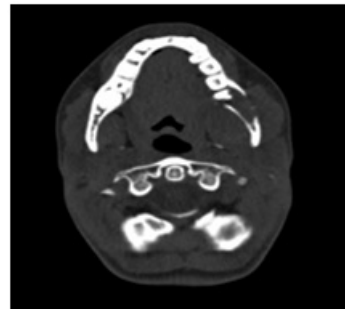


Figure 1: axial scannographic slices showing the tumor process of the left horizontal branch of mandible

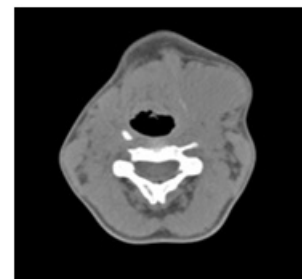


Figure 2: axial scannographic slices evidencing a left Angulo-mandibular lymphadenopathy

For diagnostic confirmation, the patient benefited from a surgical biopsy of the lesion. Microscopic analysis of the specimen showed solid sheet of small-round cell population scattered in a fibrovascular stroma. Nuclei are rounded, hyperchromatic, nucleolate and richly mitotic. The immunohistochemical complement was performed and revealed positive for CD99, vimentin and pancytokeratin, confirming the diagnosis of Ewing's sarcoma.

A whole body bone scan and a bone marrow aspiration biopsy was made and no abnormalities or distant metastases were revealed.

The patient received induction chemotherapy combining Vincristine (V), Ifosfamide (I), Adriamycin (A), Cyclophosphamide (C) and Etoposide (E) (VAC-IE) without significant adverse effects. The evaluation scan showed a tumor regression of 40%. The excisional surgery consisted of a left hemi-mandibulectomy without reconstruction. The anatomic-pathological analysis of the excisional piece showed the presence of a tumor residue estimated at 5% with a tumor jugal limit. Consolidation chemotherapy was started postoperatively. The use of radiotherapy was necessary because of the tumor margins. Radiotherapy was administered concurrently with the start of consolidation chemotherapy. The patient received a dose of 45 Gy in 1.8Gy per fraction, spread over 35 days, in technique volumetric modulated arc therapy (VMAT) (Figure 3).

After a 4-year follow-up, the patient is in good control without tumor recurrence or distant metastasis.

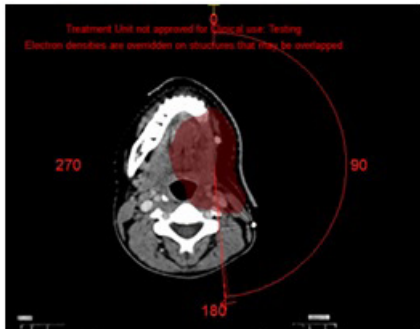


Figure 3: axial slices of the simulation CT showing the isodose distribution in VMAT technique

4. Discussion

First described by James Ewing in 1921, ES is an aggressive primitive malignant bone tumor that is radiation sensitive in contrast to osteosarcoma [4]. It affects children and young adults preferentially between 5 and 20 years, peak age is approximately 15 years [5], with a male predominance of (2:1) [6] and preferably persons of Caucasian origin [7].

ES most often develops in the lower extremity (femur 15–20%, tibia or fibula 5–10%), pelvis (20–30%), upper extremity (humerus 5–10%), ribs (9–13%), and spine (6–8%). Long bone tumors usually present in diaphysis. Cervical and facial locations are very rare, mandibular involvement represents only 0.7% of all locations observed [8].

At the time of diagnosis, 20–25% of patients have gross metastases, and nearly all patients have micrometastases. Metastasis is more in pelvic primary tumors as compared with tumors of the extremities or ribs [9, 10]. Common sites of metastases are the lungs (40%) and bones (40%), and infrequently to other sites [11].

Locoregional pain is the most common symptom presented in patients with ES, associated with mass syndrome and pathological fractures. At the mandibular level, the symptoms are misleading and non-specific causing delayed diagnosis. It is most often a mass rapidly progressive more or less painful mimicking a dental infection [12, 13]. Other symptoms may be observed such as loosening of teeth, otitis media, trismus, and paresthesia if the tumor is near to the inferior alveolar nerve [14]. As with other bone tumors, systemic symptoms such as fever, anemia, and weight loss are found in <10% of cases [15]. The mucous plane is usually healthy or erythematous and rarely ulcerated.

On a plain X-ray, the ES is defined as a destructive lesion of the bone, and takes the appearance of a lytic or sclerotic lesion. Other forms can be observed such as “moth-eaten,” “onion skinning,” or “Codman’s triangle” reaction. The presence of a periosteal bone reaction and displacement or destruction of unerupted tooth follicles have been described as the commonest radiological features for ES affecting jaw bones [16, 17]. “Onion skinning” reaction which suggested as a common radiological feature for lots of ES of the long bones, is rarely seen in jaws lesions [18, 19].

Local computed tomography (CT) and magnetic resonance imaging (MRI) are complementary needed to make the diagnosis and assess the resectability of the tumor. The CT can be used to identify bone destruction and soft tissue extent associated with Ewing’s sarcoma. Tumor size is evaluated after contrast injection, which may be a means of assessing tumor response after chemotherapy. The other advantage of the scanner is to make the differential diagnosis with osteomyelitis, fibrosarcoma or osteosarcoma.

MRI allows a precise definition of the local extension of the tumor, especially the intramedullary portion, and the relation of the tumor with the neighboring structures namely the vessels and the nerves [20].

Based on the use of FDG as a marker of tumor viability, FDG-PET-CT help to detect bone metastases not depicted on traditional bone scans, both at diagnosis and at recurrence [21]. In addition, PET-CT is the most sensitive modality for therapeutic follow-up, and detection of early changes in tumor metabolism, which is the consequence of a therapeutic response.

Because few lesions <8 mm are not detectable using FDG-PET-CT imaging, CT scans are still more accurate for the screening of lung metastases [21].

The certitude diagnosis is obtained by a biopsy of the tumor lesion, preferably surgical. Histopathological analysis reveals a diffuse proliferation of small round cells fluctuating between un-

differentiated patterns and neoplasm that show neuroectodermal differentiation [22]. Immunohistochemistry constitutes an essential means in the identification of ES, especially in the differential diagnosis with other small round cell [23]. The tumor cells are positive for vimentin and CD99 and negative for neural, skeletal, vascular and lymphoid cell markers. The present case was positive for CD99 and vimentin and negative for other immunomarkers, supports the diagnosis of ES.

More than 90% of patients have [t(11;22) or t(21;22)] involving the EWS gene on chromosome 22, and c-Myc proto-oncogene is frequently expressed.

The presence of metastases at diagnosis is the most important prognostic factor. However, patients with only lung metastasis have a better clinical outcome than those with metastases in bone or liver [24], and patients with multiple lesions are worse than those with solitary lesion. Others poor factors are: tumor size >8 cm, volume tumor >200 cc, age >17, male gender, elevated LDH and central tumors (esp. pelvis, ribs, humerus and femur) [25, 26]. Poor histologic/radiologic response to induction chemotherapy has also been identified as a major adverse prognostic factor, even when chemotherapy was followed by R0 resection [27].

Combined therapy including surgery, radiotherapy and chemotherapy is the standard in the management of ES. The multidisciplinary with effective local and systemic treatment has dramatically improved the 5-years survival rate of patients with ES from less than 16% to more than 75% of cases [28]. The Inter Group Ewing Sarcoma Study (IESS) concluded that the ES of the cervical and facial region had a better survival rate than the others regions [28].

Concerning local therapy, the strategy was switched from radiotherapy (RT) alone to surgery with or without radiotherapy. For example, the percentage of patients treated by surgery at the level of Italian centers increased from 32% in the first protocols to 72% in the most recent studies. During the same period, RT followed an inverse evolution from 68% to 28% ($P = .0001$).

No randomized trials have directly compared radiotherapy (RT) to surgery for local control (LC) of ES, but lots of retrospective studies showed better LC and event-free-survival after complete surgery (+/- followed by radiotherapy) as compared with RT alone [26, 32-34].

Surgery is indicated, if a complete surgical excision is technically possible, without compromising functional results. Surgery allows pathologic information of the tumor response after induction chemotherapy and therefore adapt consolidation chemotherapy, and reduce the risk of secondary cancers and late effects of radiotherapy, especially in young patients. In case of mandibular resection, reconstruction can be done using free flaps or induced membrane. In the metastatic situation, surgery may be helpful for limited pulmonary metastases, or palliation at primary site.

RT can be discussed in definitive or postoperative situation. In-

dications of adjuvant RT include gross residual disease (55.8 Gy), close margins (45 Gy), or poor histologic response to induction chemotherapy in resected specimen (<90% necrosis). Exclusive RT is a reasonable alternative strategy in case of skull, vertebral or pelvic primaries and for unresectable disease. Exclusive RT can also be discussed if complete surgery is difficult, especially in case of small volume. In the German series, for example, central tumors, volume <100 cm³, have a local recurrence rate after RT similar to tumors operated, with or without postoperative RT: 12.3% versus 15.9% and 11.1%. In contrast, tumors larger than 100 cm³ have a local relapse rate of 26.4% after exclusive RT versus 15.4% and 6.6% after surgery with or without RT [35]. Adjuvant RT may be challenged when these adverse effects may be more important than local control benefit; it is the case of young age, risk of surgical complications following RT, and predisposition to cancer.

Chemotherapy is given to all patients. All current trials employ 3 to 6 cycles of induction chemotherapy after biopsy, followed by local therapy and another 6 to 10 cycles of consolidation chemotherapy. Most chemotherapy regimens combined cyclophosphamide (C), doxorubicin (D), vincristine (V), actinomycin-D (A), ifosfamide (I), and etoposide (E). Compressed VAC-IE is the current standard. Induction chemotherapy is always preferred over starting systemic therapy and local therapy at the same time. The advantage of using induction chemotherapy is to reduce the size of the tumor and therefore facilitate local treatment by the surgeon or radiotherapist, and minimize tumor extension at the level of the soft tissue allowing the surgeon to achieve negative margins. Response rates to induction chemotherapy are high, with radiologic complete response and partial response rates of up to 90% reported [36].

5. Conclusion

ES is a highly aggressive tumor that very rarely affects the mandible. Because of its important metastatic power that conditions the prognosis, the diagnosis of ES must be accurate and early. Modern multimodality treatment strategy based on chemotherapy regimens neoadjuvantly and adjuvantly, in combination with surgery and/or radiotherapy for local control will aim to achieve maximum possible outcome for these patients.

6. Acknowledgment

We thank the Radiotherapy department and our radiotherapist's colleagues at the National Institute of Oncology of Rabat who provided care and support for the patient.

References

1. Vikas PB, Ahmed MBR, Bastian TS, David TP. Ewing's sarcoma of the maxilla. *Indian J Dent Res.* 2008; 19: 66-9.
2. Infante-Cossio P, Gutierrez-Perez JL, Garcia-Perla A, Noguer-Mediavilla M, Gavilan-Carrasco F. Primary Ewing's sarcoma of the maxilla and zygoma: report of a case. *J Oral Maxillofac Surg.* 2005; 63: 1539-42.
3. Karski EE, Matthy KK, Neuhaus JM, Goldsby RE, Dubois SG.

- Characteristics and outcomes of patients with Ewing sarcoma over 40 years of age at diagnosis. *Cancer Epidemiol.* 2013; 37: 29-33.
4. Angervall L, Enzinger FM. Extraskelatal neoplasm resembling Ewing's sarcoma. *Cancer.* 1975; 36: 240-51.
 5. Glass AG, Fraumeni JF. Epidemiology of bone cancer in children. *J Natl Cancer Inst.* 1970; 44: 187-99.
 6. Lopes SLPC, Almeida SM de, Costa ALF, Zanardi VA, Cendes F. Imaging findings of Ewing's sarcoma in the mandible. *J Oral Sci.* 2007; 49: 167-171.
 7. Rao BS, Rai G, Hassan S, Nadaf A. Ewing's sarcoma of the mandible. *Natl J Maxillofac Surg.* 2011; 2: 184-8.
 8. Gosau M, Baumhoer D, Ihrler S, Kleinheinz J, Driemel O. Ewing sarcoma of the mandible mimicking an odontogenic abscess _ a case report. *Head Face Med.* 2008; 4: 24.
 9. Cotterill SJ, Ahrens S, Paulussen M, Jürgens HF, Voûte PA, Craft AW. Prognostic factors in Ewing's tumor of bone: analysis of 975 patients from the European Intergroup Cooperative Ewing's Sarcoma Study Group. *J Clin Oncol.* 2000; 18: 3108-14.
 10. Ladenstein R, Pötschger U, Le Deley MC, Whelan J, Paulussen M, Oberlin O, et al. Primary disseminated multifocal Ewing sarcoma: results of the Euro-EWING 99 trial. *J Clin Oncol.* 2010; 28: 3284-91.
 11. Nesbit ME, Gehan EA, Burgert EO Jr, Vietti TJ, Tefft M, Evans R, et al. Multimodal therapy for the management of primary, nonmetastatic Ewing's sarcoma of bone: a long-term follow-up of the First Intergroup study. *J Clin Oncol.* 1990; 8: 1664-74.
 12. Gosau M, Baumhoer D, Ihrler S, Kleinheinz J, Driemel O. Ewing sarcoma of the mandible mimicking an odontogenic abscess – a case report. *Head Face Med.* 2008; 5: 24.
 13. Ko E, Brouns ER, Korones DN, Pochal WF, Philipone EM, Zegarelli DJ, et al. Primary Ewing sarcoma of the anterior mandible localized to the midline. *Oral Surg Oral Med Oral Pathol Oral Radiol.* 2013; 115: e46–50.
 14. Khanna G, Sato Y, Smith RJ, Bauman NM, Nerad J. Causes of facial swelling in pediatric patients: correlation of clinical and radiologic findings. *Radiographics.* 2006; 26: 157-71.
 15. Margaix-Muñoz M, Bagán J, Poveda-Roda R. Ewing sarcoma of the oral cavity, a review. *J Clin Exp Dent.* 2017; 9: e294-e301.
 16. Wood RE, Nortje CJ, Hesselting P, Grotepass F. Ewing's tumor of the jaw. *Oral Surg Oral Med Oral Pathol.* 1990; 69: 120-7.
 17. Yalcin S, Turoglu HT, Ozdamar S, Sadikoglu Y, Gurbuzer B, Yenici O. Ewing's tumor of the mandible. *Oral Surg Oral Med Oral Pathol.* 1993; 76: 362-7.
 18. Gorospe L, Fernández-Gil MA, García-Raya P, Royo A, López-Barca F, García-Miguel, García-Miguel P. Ewing's sarcoma of the mandible: radiologic features with emphasis on magnetic appearance. *Oral Surg Oral Med Oral Pathol Oral Radiol Endod.* 2001; 91: 728-34.
 19. Quesada JL, Alcalde JM, Espinosa JM, García-Tapia R. Ewing's sarcoma of the mandible. *J Laryngol Otol.* 2003; 117: 736-8.
 20. Mentzel HJ, Kentouche K, Sauner D, Fleischmann C, Vogt S, Gottschild D, et al. Comparison of whole-body STIR-MRI and ^{99m}Tcmethylene-diphosphonate scintigraphy in children with suspected multifocal bone lesions. *Eur Radiol.* 2004; 14: 2297-2302.
 21. Györke T, Zajic T, Lange A, Schäfer O, Moser E, Brink I, et al. Impact of FDG PET for staging of Ewing sarcomas and primitive neuroectodermal tumours. *Nucl Med Commun.* 2006; 27: 17-24.
 22. Llombart-Bosch A, Machado I, Navarro S, Bertoni F, Bacchini P, Alberghini M, et al. Histological heterogeneity of Ewing's sarcoma/PNET: an immunohistochemical analysis of 415 genetically confirmed cases with clinical support. *Virchows Arch.* 2009; 455: 397-411
 23. Llombart-Bosch A, Contesso G, Peydro-Olaya A. Histology, immunohistochemistry, and electron microscopy of small round cell tumors of bone. *Semin Diagn Pathol.* 1996; 13: 153-70.
 24. Gaspar N, Hawkins DS, Dirksen U, Lewis IJ, Ferrari S, Le Deley MC, et al. Ewing sarcoma: current management and future approaches through collaboration. *J Clin Oncol.* 2015; 33: 3036-46.
 25. Glaubiger DL, Makuch R, Schwarz J, Levine AS, Johnson RE. Determination of prognostic factors and their influence on therapeutic results in patients with Ewing's sarcoma. *Cancer.* 1980; 45:2 213-19.
 26. Rodríguez-Galindo C, Navid F, Liu T, Billups CA, Rao BN, Krasin MJ. Prognostic factors for local and distant control in Ewing sarcoma family of tumors. *Ann Oncol* 2008; 19: 814-20.
 27. Oberlin O, Deley MC, Bui BN, Philip T, Terrier P, Carrie C, et al. Prognostic factors in localized Ewing's tumours and peripheral neuroectodermal tumours: the third study of the French Society of Paediatric Oncology (EW88 study). *Br J Cancer.* 2001; 85: 1646-54.
 28. Lopes SL, Almeida SM, Costa AL, Zanardi VA, Cendes F. Imaging findings of Ewing's sarcoma in the mandible. *J Oral Sci.* 2007; 49: 167-71.
 29. Siegal GP, Olivier WR, Reinus WR, Gilula LA, Foulkes MA, Kissane JM, et al. Primary Ewing's sarcoma involving the bones of the head and neck. *Cancer.* 1987; 60: 2829-40.
 30. Bacci G, Longhi A, Briccoli A, Bertoni F, Versari M, Picci P. The role of surgical margins in treatment of Ewing's sarcoma family tumors: experience of a single institution with 512 patients treated with adjuvant and neoadjuvant chemotherapy. *Int J Radiat Oncol Biol Phys.* 2006; 65: 766-72.
 31. Bacci G, Longhi A, Ferrari S, Mercuri M, Versari M, Bertoni F. Prognostic factors in non-metastatic Ewing's sarcoma tumor of bone: an analysis of 579 patients treated at a single institution with adjuvant or neoadjuvant chemotherapy between 1972 and 1998. *Acta Oncol.* 2006; 45: 469-75.
 32. Bacci G, Ferrari S, Bertoni F, Rimondini S, Longhi A, Bacchini P, et al. Prognostic factors in nonmetastatic Ewing's sarcoma of bone treated with adjuvant chemotherapy: analysis of 359 patients at the Istituto Ortopedico Rizzoli. *J Clin Oncol.* 2000; 18: 4-11.
 33. Donaldson SS, Torrey M, Link MP, Glicksman A, Gilula L, Man-

- ning J, et al. A multidisciplinary study investigating radiotherapy in Ewing's sarcoma: end results of POG #8346. Pediatric Oncology Group. *Int J Radiat Oncol Biol Phys.* 1998; 42:125-35.
34. Obata H, Ueda T, Kawai A, Ishii T, Ozaki T, Abe S, et al. Clinical outcome of patients with Ewing sarcoma family of tumors of bone in Japan: the Japanese Musculoskeletal Oncology Group cooperative study. *Cancer.* 2007; 109: 767-75.
35. Schuck A, Ahrens S, Paulussen M, Kuhlen M, Könemann S, Rube C, et al. Local therapy in localized Ewing tumors: results of 1058 patients treated in the CESS 81, CESS 86, and EICESS 92 trials. *Int J Radiat Oncol Biol Phys.* 2003; 55: 168-77.
36. Oberlin O, Patte C, Demeocq F, Lacombe MJ, Brunat-Mentigny M, Tron P, et al. The response to initial chemotherapy as a prognostic factor in localized Ewing's sarcoma. *Eur J Cancer Clin Oncol.* 1985; 21: 463-7.