

A Review for Diagnostic Inaccuracy of Pure Ductal Carcinoma Insitu in Multiple Fibroadenomas and Axillary Nodal Involvement

Ilhan B, Kut A*, Emiroglu S and Turkay R

Department of General Surgery, University of Istanbul, Istanbul Faculty of Medicine, Turkey

*Corresponding author:

Abdullah Kut,
Department of General Surgery, University
of Istanbul, Istanbul Faculty of Medicine,
İstanbul Tıp Fakültesi Çapa – Fatih,
İSTANBUL, Tel: +90 2124142000,
Fax: +90 2126358522,
E-mail: abdullah.kut@gmail.com

Received: 20 Mar 2021

Accepted: 06 Apr 2021

Published: 12 Apr 2021

Copyright:

©2021 Kut A. This is an open access article distributed under the terms of the Creative Commons Attribution License, which permits unrestricted use, distribution, and build upon your work non-commercially.

Citation:

Kut A. A Review for Diagnostic Inaccuracy of Pure Ductal Carcinoma Insitu in Multiple Fibroadenomas and Axillary Nodal Involvement. *Ann Clin Med Case Rep.* 2021; V6(11): 1-3.

Keywords:

Breast; Surgery; Ductal carcinoma in-situ; Fibroadenoma; Axillary nodal metastasis

Author Contribution:

Ilhan B, Kut A, Emiroğlu S, Türkay R, these authors are contributed equally to this article.

1. Abstract

Fibroadenomas (FA), are common benign tumor of the breast, can be treated with simple excision. Breast cancer arising within FA is a rare phenomenon.

We report a 47-years old female, admitted to Istanbul Faculty of Medicine Department of Surgery and presented with multiple breast lumps and axillary suspected lymph node of three months duration. Patient underwent a lumpectomy, sentinel lymph node biopsy. 4 FAs were identified. In FAs ductal carcinoma in-situ (DCIS) were detected. In the sentinel lymph node there was a subcapsular circumscribed DCIS-like foci measuring detected. No further disease was observed in 5 year follow-up.

4 FAs were identified. In a FA 2 mm ductal carcinoma in-situ (DCIS), in another 1,5 mm DCIS, microcalcifications and atypical lobular hyperplasia were detected. In the sentinel lymph node there was a subcapsular circumscribed DCIS-like foci measuring 1,25 mm, within a 3 mm glandular inclusion. The morphology of DCIS-like lesion in the lymph node was similar to DCIS within FAs.

This report aimed to attract attention to the the need for extensive tissue sampling in multiple FAs as the clinicoradiological features of malignant transformation may be quite suitable to be easily missed on routine examination.

2. Introduction

Benign breast disease has a high prevalence rate with fibroadenoma (FA) occurring in one of every five women and one of every two women is affected by fibrocystic disease FAs, a biphasic tumor with stromal and epithelial component, are benign tumors of not much concern. Malignant transformation in a FA is an uncommon feature [1].

Ductal carcinoma in-situ (DCIS) of the breast the tumour is confined within the ducts without invading the periductal stroma. Tumour spread has not yet occurred, as reflected by the favourable long-term breast cancer-specific mortality rate of 1-2 percent [2].

DCIS can be diagnosed reliably only after careful histological investigation requiring extensive tumour sampling to exclude invasion. A drawback of core biopsy is the limited sampling of a lesion, and therefore we report this case without adequate core biopsy diagnosis, but DCIS diagnosis after definitive pathologic examination.

3. Clinical Summary

A 47-years old woman presented with history of lump in the left breast of three month duration. Patient admitted from another clinic with diagnoses of malignant phyllodes tumor and multiple fibroadenoma (FA) of the left breast according to core biopsies. There was no family history of breast or ovarian lesions in the past.

Patient had regular menstrual cycles and last child birth 12 years back. Patient's core biopsy materials were consulted to institutional pathology department. Pathology department reported that there was no suspicious of malignancy findings in the available materials except FA features.

On examination, a freely mobile firm mass was felt in left upper outer quadrant measuring 3 × 2 cm in size. Multiple smaller mobile lumps ranging in size from 0.5 cm to 1 cm were also palpable in upper quadrant near the axillary tail. There was no palpable lymph node in the left axilla. Mammography (MG) was not clearly diagnostic because of high density of breast tissue, however MG revealed multiple small round nodular lesions with smooth margins and a larger lesion in the left breast on upper inner quadrant (Figure 1). Ultrasonography(USG) of left breast showed well-defined round to oval shaped hypoechoic lesions with smooth to macrolobulated margins. Magnetic resonance imaging(MRI) revealed similar findings, also MRI detected one suspected malignant lymph node in the left axilla. With surgeon's opinion and patient's request patient underwent a lumpectomy to the left upper outer quadrant and sentinel lymph node biopsy(SLNB).

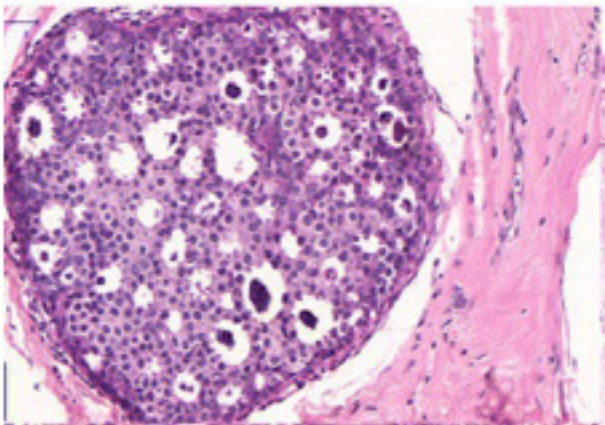


Figure 1: CC graphy shows multiple FAs on left breast outer quadrant

4. Pathological Findings

In definitive pathologic examination 4 FAs were identified. In a FA 2 mm ductal carcinoma in-situ(DCIS) (Figure 2), in another 1,5 mm DCIS, microcalcifications and atypic lobular hyperplasia were detected. In the sentinel lymph node there was a subcapsular circumscribed DCIS-like foci measuring 1,25 mm, within a 3 mm glandular inclusion. The morphology of DCIS-like lesion in the lymph node was similar to DCIS within FAs. The DCIS in FAs and lymph node were estrogen and progesterone receptor positive, *cerb-2* negative. A circumferential cavity shaving as reexcision, which involved an intercanalicular FA and postoperative breast tissue, was performed. Prophylaxis was continued with hormone therapy. No further disease was observed in 5 year follow-up period.

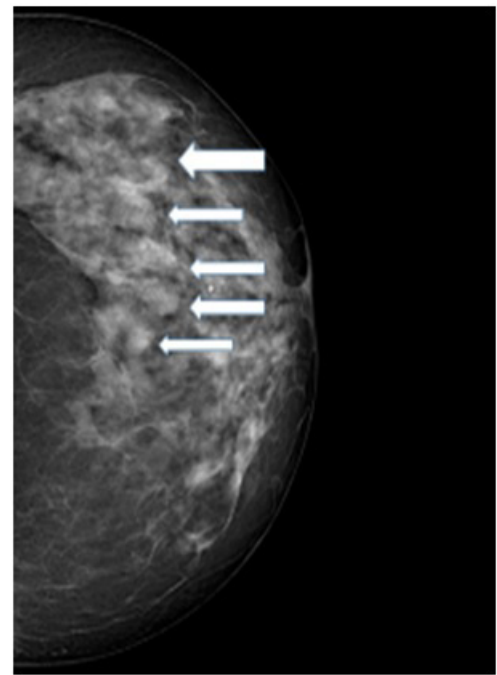


Figure 2: DCIS with microcalcifications (HE X 20)

5. Discussion

Epithelial hyperplasia within fibroadenomas(FAs) is a common finding and infrequently atypical hyperplasia of ductal or lobular type may also be noted. Carter et al. found atypical hyperplasia in 0.8 - 1% of FAs [4].

Review of literature reveals few case studies with in situ/ invasive ductal and lobular carcinoma in a FA These findings draw our attention to rather rare events that occurs in a FA ranging from epithelial hyperplasias to in-situ or invasive carcinomas. Progression of epithelial component into in situ and invasive carcinomas is quite rare that occurs usually in women over 40 years [5].

Ductal carcinoma in-situ (DCIS) is a lesion which has a theoretical risk of 0% for metastases, axillary metastases have been found in 1-2% of the patients treated with axillary dissection. In a metaanalysis of 3166 patients, the incidence of sentinel lymph node(SLN) metastases was 7.4% in patients with a preoperative diagnosis of DCIS compared with 3.7% in patients with a definitive postoperative diagnosis of DCIS alone. Furthermore, SLN positivity in DCIS is higher than reported axillary positivity ranging between 1% and 13% in published reports [6-8]. In this present study a SLNB was performed according to suspicious of axillary lymph node by imaging and in this lymph node a small DCIS foci in an epithelial inclusion was detected.

To conclude, this case report highlights the need for extensive tissue sampling in multiple FAs as the clinicoradiological features of malignant transformation may be quite suitable to be easily missed on routine examination.

6. Acknowledgment

We are grateful to Istanbul University Pathology Department for the excellent breast histopathological section.

7. Ethical Approval

All procedures performed in studies involving human participants were in accordance with the ethical standards of the institutional research committee and with the 1964 Helsinki declaration and its later amendments or comparable ethical standards.

References

1. Friedenreich C, Bryant H, Alexander F, Hugh J, Danyluk J, Page D. Risk factors for benign proliferative breast disease. *Int J Epidemiol*. 2000; 29: 637-44. (PMID: 10922339).
2. Ernster VL, Barclay J, Kerlikowske K, H Wilkie, R Ballard-Barbash. Mortality among women with ductal carcinoma in situ of the breast in the population-based surveillance, epidemiology, and end results program. *Arch Intern Med* 2000; 160: 953-958. (PMID: 10761960).
3. EORTC Breast Cancer Cooperative Group; EORTC Radiotherapy Group; Nina Bijker, Philip Meijnen, Johannes L Peterse, et al. Breast-conserving treatment with or without radiotherapy in ductal carcinoma-in-situ: ten-year results of European Organisation for Research and Treatment of Cancer randomized phase III trial 10853 – a study by the EORTC Breast Cancer Cooperative Group and EORTC Radiotherapy Group. *J Clin Oncol* 2006; 24: 3381-3387. (PMID: 16801628).
4. Carter CL, Corle DK, Micozzi MS, Schatzkin A, Taylor PR. A prospective study of the development of breast cancer in 16, 692 women with benign breast disease. *Am J Epidemiol* 1988; 128: 467-77. (PMID: 3414655).
5. Kuijper A, Preisler-Adams SS, Rahusen FD, Gille JJP, Wall EV, Van Diest PJ. Multiple fibroadenomas harbouring carcinoma in situ in a woman with a family history of breast/ovarian cancer. *J Clin Pathol* 2002; 55: 795-7. (PMID: 12354814).
6. Intra M, Rotmensz N, Veronesi P, Colleoni M, Iodice S, Paganelli G, et al. Sentinel node biopsy is not a standard procedure in ductal carcinoma in situ of the breast: the experience of the European Institute of Oncology on 854 patients in 10 years. *Ann Surg*. 2008; 315-319. (PMID: 18216539).
7. Katz A, Gage I, Evans S, Shaffer M, Fleury T, Smith FP, et al. Sentinel lymph node positivity of patients with ductal carcinoma in situ or microinvasive breast cancer. *Am J Surg*. 2006; 191(6); 761-766. (PMID: 16720145).
8. Klauber-DeMore N, Tan LK, Liberman L, Kaptain S, Fey J, Borgen P, et al. Sentinel lymph node biopsy: is it indicated in patients with high-risk ductal carcinoma-in-situ and ductal carcinoma-in-situ with microinvasion?. *Ann Surg Oncol* 2000; 636–642. (PMID: 11034239).