

The Role of Strain Echocardiography in the Early Diagnosis of AL Type Cardiac Amyloidosis: A Case Report

Dogan M^{1*}, Şener YZ¹, Kaya B¹, Goker H², Leblebici CB³

¹Hacettepe University Faculty of Medicine, Department of Cardiology, Ankara, Turkey

²Hacettepe University Faculty of Medicine, Department of Hematology, Ankara

³Hacettepe University Faculty of Medicine, Department of Pathology, Ankara, Turkey

*Corresponding author:

Mert Dogan,

Faculty of Medicine, Department of Cardiology,
Hacettepe University, Turkey,

Tel: +90 533 191 9523,

E-mail: drmertd@gmail.com

Received: 05 Mar 2021

Accepted: 27 Mar 2021

Published: 02 Apr 2021

Copyright:

©2021 Dogan M. This is an open access article distributed under the terms of the Creative Commons Attribution License, which permits unrestricted use, distribution, and build upon your work non-commercially.

Citation:

Dogan M. The Role of Strain Echocardiography in the Early Diagnosis of AL Type Cardiac Amyloidosis: A Case Report. *Ann Clin Med Case Rep.* 2021; V6(10): 1-3.

Keywords:

Immunoglobulin light-chain amyloidosis; Multiple myeloma, Strain echocardiography

1. Summary

Cardiac amyloidosis is a progressive cardiomyopathy that results from the accumulation of disrupted endogenous proteins in the heart in the form of amyloid fibrils. Diagnosing cardiac amyloidosis is a difficult process for clinicians and requires suspicion first. AL type cardiac amyloidosis is the most fatal type compared to other types of cardiac amyloidosis. Therefore even if it is asymptomatic, it is necessary to be skeptical in terms of cardiac involvement in every patient with AL type amyloidosis. In this case report, a 55-year-old female patient was admitted to our hospital to be investigated for multiple myeloma after being diagnosed with primary amyloidosis in an other center. As a result of the examinations, our patient was diagnosed with multiple myeloma. We suspected cardiac amyloidosis in our patient, for whom we performed routine strain Echocardiography (ECHO) before chemotherapy. We diagnosed cardiac amyloidosis with cardiac Magnetic Resonance Imaging (MRI).

2. Introduction

In amyloidosis, misfolded protein (amyloid) deposits in the cardiac interstitium, interrupt the normal myocardial contractile units and causes restriction. Most commonly, the misfolded protein is either immunoglobulin light chain (AL type) or transthyretin (TTR type) [1]. Cardiac Amyloidosis (CA) can be qualified as primary (AL type), secondary (reactive, AA type), hereditary, senile system-

ic or isolated atrial amyloidosis [2]. Cardiac involvement in AL type amyloidosis is the most important parameter of prognosis, so many studies have focused on the mechanism of cardiac dysfunction [3]. Although the cardiac dysfunction mechanism cannot yet be fully explained, it has been shown that mortality in advanced stages of AL-type CA is quite high and reveals the importance of early diagnosis. In this report, we will discuss a case of CA that we caught during the asymptomatic period in a patient with prior diagnoses of primary amyloidosis and hypertension.

3. Case Presentation

The patient with the diagnosis of hypertension and primary amyloidosis applied to our hospital to be investigated for multiple myeloma. The patient had a complaint of low back pain on initial presentation. In the physical examination, the liver was palpated 2 cm in the right subcostal area. The patient had no other abnormal findings. In laboratory investigation, complete blood count was normal, albumin 2.55 g/dl, globulin 5.05 g/dl, total protein 7.60 g/dl, blood kappa/lambda ratio 2.78, IgA 696 mg/dl, IgG 2640 mg/dl, IgM 271 mg/dl, free lambda light chain 40.7 mg/dl, and free kappa light chain was 113 mg/dl. The patient's lumbar spinal Computed Tomography (CT) revealed multiple bone lesions, collapse fracture in T₁₁ vertebral corpus which resulted in 80% loss of height and narrowing of the spinal canal at this level, and stenosis in both lateral recesses and neural foramens. The patient was examined

with bone marrow and liver biopsy to investigate the etiology of hepatomegaly and hematologic disease. Bone marrow pathology revealed increased megakaryocytes, normocellular bone marrow, and amorphous eosinophilic substance accumulation. In the immunohistochemical study, 10% of cells were stained with CD138, and kappa staining was observed. Staining was detected in up to 10% of cells interspersed with CD20 and CD3 into the marrow distance. Cyclin D1 was negative. Amyloid accumulation was detected in the vessel walls. In the histopathological examination of the liver biopsy, Congo red positive diffuse amyloid accumulation in liver tissue polytypic staining with kappa and lambda were observed (Figure 1). The patient was diagnosed with multiple myeloma because of the increase in the globulin fraction, the increase in light chain concentrations, lytic lesions in the bone tissue, kappa / lambda ratio of 2.78 and the presence of 10% plasma cells in the bone marrow. Cyclophosphamide and dexamethasone chemotherapy (CTx) was planned for the patient. The Department of Cardiology was consulted for approval before CTx. In the laboratory

analysis of the patient, BNP and Troponin-I were 223.2 pg/mL and 16.3 ng/ml, respectively. Electro Cardio Graphy (ECG) examination of the patient was evaluated as sinus rhythm and no pathological finding was detected. The patient had a history of a coronary angiography procedure one year ago which had revealed normal coronary arteries. The strain Echocardiography (ECHO) imaging revealed reduced strain in the left ventricle in which the apical region was spared (Figure 3). The ejection fraction was 60% and left ventricular systolic function was normal. Cardiac Magnetic Resonance Imaging (CMRI) was performed because ECHO findings suggested CA. The patient's cardiac MRI revealed normal myocardial thickness, subendocardial diffuse contrast enhancement in the anterior lateral and inferolateral wall of the left ventricle (Figure 2). Since the patient did not have systolic or diastolic dysfunction, rhythm disturbances, and clinical symptoms at this stage, the patient was not scheduled for treatment and followed up closely. The patient was cleared by the Cardiology Department CTx and the patient's treatment was started.

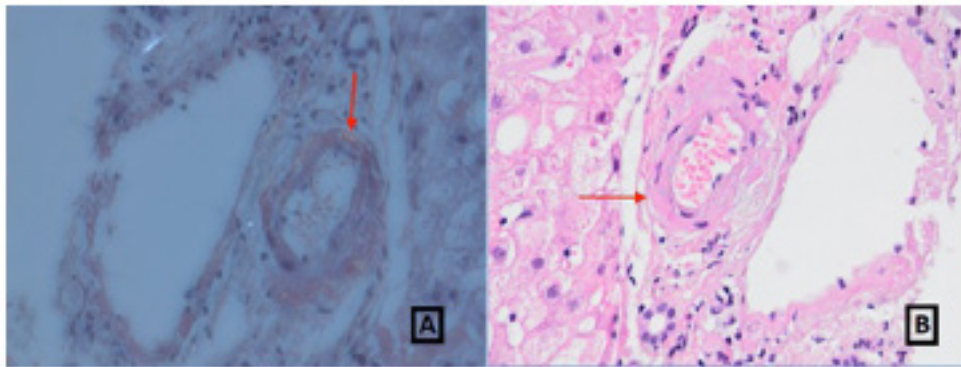


Figure 1: H&E staining, 40x. Pathological image of the patient's liver needle biopsy. Accumulation of dense, amorphous and eosinophilic material in the hepatic artery wall. Inset shows the Congo red staining (A, B)

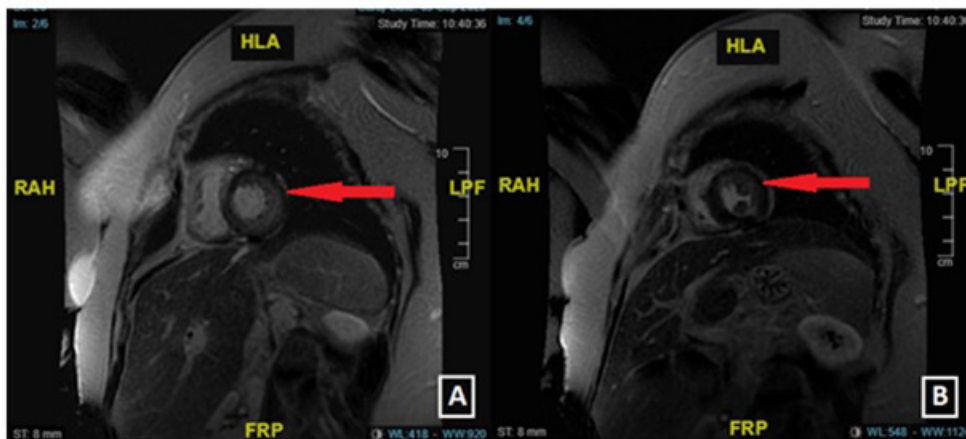


Figure 2: Diffuse subendocardial diffuse enhancement images, prominent in the left ventricular anterior lateral and inferolateral walls on cardiac MRI (A, B)

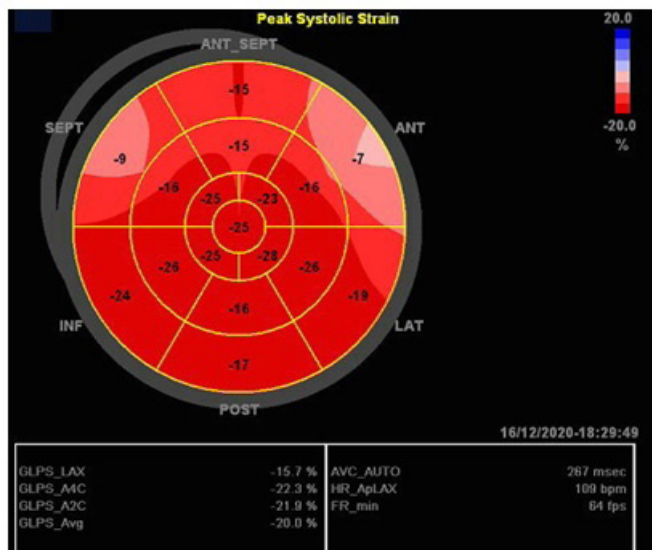


Figure 3: Strain echocardiography image supporting cardiac amyloidosis in the inferolateral wall, evident in the anterolateral and septal wall, with the apex area preserved.

4. Discussion

CA is progressive cardiomyopathy that occurs as a result of the accumulation of disrupted endogenous proteins in the form of amyloid fibrils in the heart and mostly together with the kidney, liver, gastrointestinal system, and soft tissue involvements. Symptoms and signs of cardiac amyloidosis include arrhythmias due to conduction defects and congestive heart failure [4]. Approximately 50-70% of patients with AL type systemic amyloid have cardiac involvement [5]. The prognosis is poor in AL amyloidosis with cardiac involvement, and the mean survival in immunoglobulin light chain CA is reported to be around 6 months [2]. It has been shown that prognosis can be significantly improved with early diagnosis and treatment. However, studies show that early diagnosis of CA is a diagnostic challenge. Until a patient diagnosed with CA, more than one clinician needs to see it, which can take up to 1 year [6].

CA can be diagnosed with a noninvasive approach using advanced imaging techniques. ECHO is a useful method for diagnosis, follow-up, and estimating prognosis in patients with CA [4]. In our case, although we did not have any pathological findings in trans-thoracic ECHO, we tested basal deformation in which the apex was preserved in strain ECHO imaging. We detected a longitudinal strain ratio of > 2.1 in the septum basal and apical region, which allowed us to exclude fabry disease and hypertension-induced hypertrophy. In addition, the preservation of the apical region allows it to distinguish CA from left ventricular hypertrophy due to aortic stenosis and hypertrophic cardiomyopathy [5]. Vogelsberg et al. reported that CMRI sensitivity is 80% and specificity is 94% for the diagnosis of CA [7]. As a result of the CMRI applied to the patient, we detected subendocardial diffuse contrast enhancement similar to the areas we found on strain ECHO. We did not perform

cardiac tissue biopsy in our patient due to the high risk of complications. We diagnosed our patient with CA in the asymptomatic period. Because the patient was diagnosed with multiple myeloma, we evaluated it as AL-type CA.

The overall goal of treatment in AL-type CA is to normalize free light chain concentrations and eradicate the monoclonal paraproteins from the blood and urine [8]. In previous studies, it was observed that patients have a clinically positive response, although there was no improvement in the ECHO parameters measured after the treatment of primary disease in AL type cardiac amyloidosis [2]. Since our patient was asymptomatic, there was no conduction defect in his ECG rhythm, the LV systolic functions were within normal limits on ECHO imaging, and there was no diastolic dysfunction, we did not give any treatment to our patient at this stage. Our patient, who received the current multiple myeloma treatment, was closely followed up by the Department of Cardiology.

AL-type CA has a higher mortality rate compared to other CA types. In AL-type CA, which usually occurs secondary to hematological diseases such as multiple myeloma, non-Hodgkin lymphoma, and monoclonal gammopathy of unknown significance, the mean survival is 6 months after heart failure develops [5]. As a result, this reveals the importance of early diagnosis and treatment. This case shows that it is possible to diagnose CA in the asymptomatic period. When the diseases causing AL-type amyloid accumulation are diagnosed, strain ECHO imaging in terms of cardiac amyloidosis in the earlier period can be included in routine clinical recommendations.

References

1. The Washington Manual of Medical Therapeutics. 36th ed. 2020.
2. Guan J, Mishra S, Falk RH, Liao R. Current perspectives on cardiac amyloidosis. *Am J Physiol Heart Circ Physiol.* 2012; 302: 544-52.
3. Milani P, Merlini G, Palladini G. Light Chain Amyloidosis. *Mediterr J Hematol Infect Dis.* 2018; 10: e2018022.
4. Brian P, Griffin, Venu M. *Manual of Cardiovascular Medicine.* 2018.
5. Cavusoglu Y, Ozpelit E, Celik A, Ikitimur B, Kayikcioglu M, Tokgozoglu L et al. Kardiyak amiloidoz: Tanı ve tedavide yenilikler. *Turk Kardiyol Dern Ars.* 2019; 47: 1-34.
6. Lousada I, Comenzo RL, Landau H, Guthrie S, Merlini G. Light Chain Amyloidosis: Patient Experience Survey from the Amyloidosis Research Consortium. *Adv Ther.* 2015; 32: 920-8.
7. Vogelsberg H, Mahrholdt H, Deluigi CC, Yilmaz A, Greulich EMKS, Klingel K et al. Cardiovascular magnetic resonance in clinically suspected cardiac amyloidosis: noninvasive imaging compared to endomyocardial biopsy. *J Am Coll Cardiol.* 2008; 51: 1022-30.
8. Siddiqi OK, Ruberg FL. Cardiac Amyloidosis: An Update on Pathophysiology, Diagnosis, and Treatment. *Trends Cardiovasc Med.* 2018; 28: 10-21.