

## Familial Mediterranean Fever Complicated by Henoch-Schönlein Purpura and Polyarteritis Nodosa in an Adult: A Case Report

Bonnard G<sup>1,\*</sup>, Abed D<sup>2</sup>, Masseur A<sup>1</sup>, Espitia A<sup>1</sup>, Artifoni M<sup>1</sup>, Néel A<sup>1</sup> and Hamidou M<sup>1</sup>

<sup>1</sup>Department of Internal Medicine, CHU Nantes, Université de Nantes, Nantes, France

<sup>2</sup>Department of Radiology, CHU Nantes, Université de Nantes, Nantes, France

### \*Corresponding author:

Guillaume Bonnard,  
Department of Internal Medicine,  
CHU Nantes,  
Université de Nantes,  
Nantes, France,  
E-mail: gp.bonnard@gmail.com

Received: 15 Oct 2020

Accepted: 02 Nov 2020

Published: 07 Nov 2020

### #Author Contributions:

GB and MH wrote the manuscript. All others authors participated in the care of patient

### Copyright:

©2020 Bonnard G. This is an open access article distributed under the terms of the Creative Commons Attribution License, which permits unrestricted use, distribution, and build upon your work non-commercially.

### Citation:

Bonnard G, Familial Mediterranean Fever Complicated by Henoch-Schönlein Purpura and Polyarteritis Nodosa in an Adult: A Case Report. *Annals of Clinical and Medical Case Reports*. 2020; 5(1): 1-4.

### Keywords:

Familial Mediterranean fever; Auto-inflammatory disease; Henoch-Schönlein purpura; Polyarteritis nodosa; Vasculitis

### 1. Abstract

Familial Mediterranean Fever (FMF) is the most frequent hereditary auto-inflammatory disease due to a mutation of the MEFV (Mediterranean fever) gene and belongs to the monogenic periodic fever syndromes. Familial Mediterranean fever has a particular ethnic distribution around the Mediterranean Sea and the diagnosis is mainly clinical, supported by genetic MEFV assay. In some cases, FMF can associate with other inflammatory diseases like various types of systemic vasculitis. We report herein a rare case of biopsy proven Henoch-Schönlein purpura in 56-year-old man with known FMF. Despite treatment by prednisone the evolution was unfavorable. He developed roughly a large subcapsular hematoma of the left hepatic lobe in relation with a ruptured aneurysm of the left hepatic artery. This vascular involvement was consistent with the diagnosis of PAN. Intravenous pulses of steroids associated with IV cyclophosphamide permitted a complete response. Association between FMF and Henoch-Schönlein purpura or polyarteritis nodosa are already reported in literature but consecutively onset of the two entities in a same adult patient with FMF is original. Diagnosis can be difficult in this setting, because of the similarities of FMF and vasculitis symptoms. Physicians should be aware about this association, and research vasculitis in case of a persistent episode of FMF over 72h, or with associated weight loss, renal impairment or any other atypical involvement.

2. Abbreviations: FMF: Familial Mediterranean Fever; MEFV: Mediterranean Fever); HSP: Henoch-Schönlein purpura; PAN: Polyarteritis Nodosa; PFMS: Protracted Febrile Myalgia Syndrome; ANCA: Anti-Neutrophil Cytoplasmic Antibodies; IL-1 $\beta$ : Interleukin 1 $\beta$ ; CT: Computed Tomography

### 3. Background

Familial Mediterranean Fever (FMF) is the most frequent hereditary auto-inflammatory disease and belongs to the monogenic periodic fever syndromes. It is characterized by recurrent episodes of fever lasting about 12-72 hrs, sometimes accompanied by serositis (peritoneal, pleural, vaginal testicular, pericardial), arthritis or erysipela-like skin eruption. The most feared long-term complication is the development of amyloid A (AA) amyloidosis-related renal disease, due to repeated inflammatory state. FMF is due to a mutation of the MEFV (Mediterranean Fever) gene, with an autosomal recessive inheritance pattern and has a particular ethnic distribution around the Mediterranean Sea. The diagnosis of FMF is mainly clinical, and several main diagnostic criteria are proposed in literature [1, 2]. MEFV genetic analysis can support but not exclude the diagnosis [3]. Fever, orchitis, arthralgias or myalgias could occur as manifestations of FMF. They could also be the symptoms of associated vasculitis, foremost Henoch-Schönlein purpura (HSP) and polyarteritis nodosa (PAN) [4]. We reported herein an original case of an adult patient with FMF who developed HSP and PAN

successively. Such a rare association of these 3 diseases is reported in literature and suggests a pathogenic link between them.

#### 4. Case report

A 56-year-old man was admitted to hospital in December 2012 for polyarthritis, lower limb purpura and persistent orchitis. He was known to have FMF since the age of 10, treated with long term colchicine. He was of Sephardic Jewish origin, and MEFV mutation status was unknown.

At admission to our department, the patient had fever associated with ankles, left knee, wrists and proximal interphalangeal joints inflammatory arthralgias, myalgia, abdominal pain without diarrhea and left scrotal pain. Physical examination disclosed lower limb purpura, edematous skin infiltrate of upper and lower limbs, and confirmed left orchitis. General condition was preserved. He had no mouth ulcers or gastrointestinal symptoms.

C-reactive protein was 256 mg/L and fibrinogen 10 g/L. The blood cell count, liver enzymes and creatinine phosphokinase levels were normal. Serum creatinine level was 70  $\mu$ mol/L. 24-hour urine protein measurements were at 0.8 g/24h, and urine cytology revealed microscopic hematuria without infection. Serum electrophoresis revealed hypoalbuminemia (28 g/L), without monoclonal gammopathy. Serum IgA level was 4.3 g/L (N: 1-3.3 g/L).

The detection of antinuclear antibodies by Hep2 immunofluorescent assay was weakly positive at 1/160, with no specificity against double-stranded DNA or nuclear antigens by ELISA assay. Anti-neutrophil cytoplasmic antibodies (ANCA) testing was negative, with normal C3 and C4 complement levels. Hepatitis B virus, Hepatitis C virus, Human immunodeficiency virus, Epstein Barr virus, syphilis, B19 parvovirus serologic tests were non-contributive. Blood, saliva and stools for PCR *Tropheryma. whipplei* were negative. Patient was negative for HLA B27, and HLA B51 was not evaluated.

Thoracic, abdominal and pelvic Computed Tomography (CT) scan revealed parietal thickening of the proximal ileum with submucosal edema, a combed aspect of the mesentery, and a peritoneal effusion of small abundance. Cutaneous biopsy of the purpura highlighted leukocytoclastic vasculitis with IgA and C3 deposits consistent with the diagnosis of HSP. Renal biopsy was not performed, and biopsy of accessory salivary glands was normal without AA amyloidosis.

He was treated with 1 mg/kg/d of prednisone, and a few days after steroids introduction, he developed an acute anemia (hemoglobin level: 4.6 g/L) without external bleeding. CT scan showed a large subcapsular hematoma of the left hepatic lobe in relation with a ruptured aneurysm of the left hepatic artery (Figure 1). There was no clinically evidence of Behcet disease, and the presence of this medium-size vessel vasculitis suggested the diagnosis of PAN. Angiography was not performed.

During his stay, he presented a deterioration of his general condition with fever, important weight loss, cophosis and mononeuritis of the median nerve.

Induction treatment by intravenous pulses of steroids associated with intravenous cyclophosphamide (600 mg/m<sup>2</sup> every 3 weeks) was started, with a positive and complete response. After induction treatment, azathioprine (2 mg/kg/day) was introduced as maintenance therapy for 2 years. With four years of follow up, the patient is well, under colchicine treatment, without vasculitis relapse.

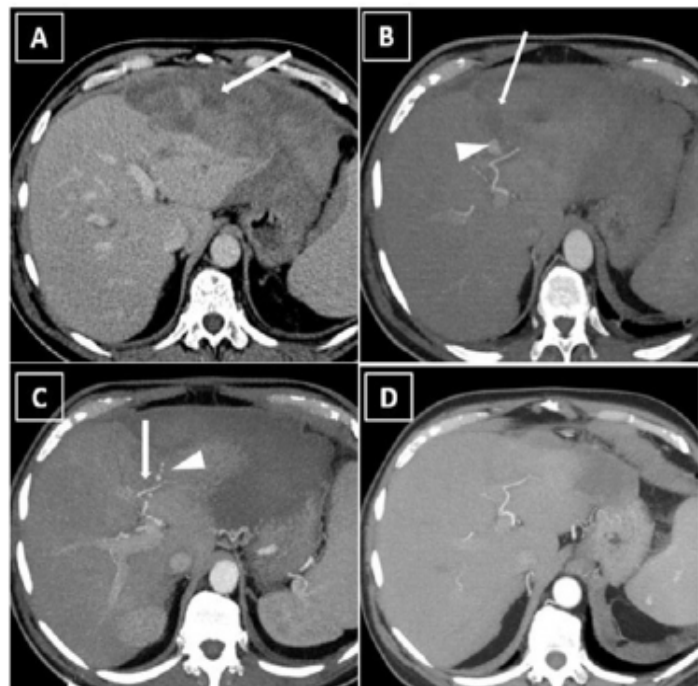


Figure 1: Contrast-enhanced CT scan during acute hemorrhagic event and follow-up(A-D). (A) Axial CT at portal venous phase showing bulby sub-capsular hematoma (arrow). (B) Axial CT at arterial phase, showing a well-defined pseudoaneurysm (arrow) of the left hepatic artery (arrowhead). (C) Axial CT at arterial phase, 10 days after hemorrhagic event and medical treatment showing thrombosis of left hepatic pseudoaneurysm (arrow) and multiples small pseudoaneurysm (arrowhead). (D) Axial CT at Arterial phase, 3 months after treatment complete normalization of CT images.

#### 5. Discussion and Conclusion

Familial Mediterranean fever can associate with others inflammatory diseases like spondylarthritis [5], inflammatory bowel disease in children [6], and various types of vasculitis [4]. The most frequently reported vasculitis associated with FMF are HSP, PAN and protracted febrile myalgia syndrome (PFMS).

HSP or IgA vasculitis is a small sized vessel vasculitis mediated by IgA and immune complex. HSP is the most common systemic vasculitis associated to FMF [4], with a prevalence estimated from 2.7 to 7.2% [7]. Its incidence in patients with FMF is 250–500-fold

higher than in the general population [8]. In the same way, prevalence of MEFV mutations in patients with HSP was significantly higher than the general population, especially the homozygous or compound heterozygous [9]. This suggests a link between these two diseases. More, many authors reported association of FMF and HSP. The presence of MEFV mutation seems not to modify the clinical presentation of HSP [9]. However few studies report higher inflammatory parameters and IgA concentration, more scrotal involvement, more edema and arthritis, and a younger age at HSP onset for MEFV mutation carriers [8, 10, 11].

Polyarteritis nodosa is a systemic necrotizing vasculitis of medium-sized arteries [12]. The main well identified environmental factor is hepatitis B virus (HBV) infection. One of the main characteristic of the disease is presence of microaneurysms typically affect renal, hepatic, and mesenteric arteries. PAN is the second most frequent vasculitis, after HSP, associated to FMF. Prevalence is estimated approximately 0.9 to 1.4% of case in FMF patients, which is higher than in the general population. The association between PAN and FMF was reported in 25 retrospective studies, with a total of 61 patients [7]. As for HSP, the presence of MEFV mutation seems to be a predisposing feature to develop PAN. The prevalence of MEFV mutation in Turkish childhood with PAN was 38%, which is nearly twice as much as the carrier rate in the Turkish population [13]. Patients with PAN associated to FMF tended to be younger at PAN onset than isolated PAN [14]. They were more frequently men gender, they had less peripheral nervous system involvement, less arthralgia/arthritis and less cardiac involvement. Conversely, they had more frequent perirenal hematoma and central nervous system involvement in half of cases and in one third of cases respectively [7, 15, 16].

Interestingly, different vasculitis occurred in siblings with FMF was reported [17]. One girl with FMF developed PAN with perirenal hematoma at 13 years old. Two years later at the age of 19 years, the older sister developed an HSP with renal involvement. We found in English literature, only one case of association of FMF, PAN and HSP in the same patient [18]. To the best of our knowledge, our patient is the first report of association of FMF, PAN and HSP in the same adult patient.

Our adult patient fulfilled classical clinical FMF criteria. Arthralgia, microscopic hematuria, lower limb purpura with proved IgA deposits in cutaneous biopsy, and elevated serum IgA level are consistent with HSP diagnosis. When hemorrhagic complication due to hepatic aneurysm occurs, the patient fulfilled the ACR criteria for PAN. Others impairment like persistent fever, weight loss, coprophagia, neuropathy, hypertension, severe myalgia was also consistent with this diagnosis.

Exact pathogenesis of FMF-associated vasculitis remains unknown. The main hypothesis frequently admitted is that genetic

factors may contribute to vasculitis development [4]. Most of patients reported with FMF-associated to vasculitis had MEFV mutation, especially homozygous or compound heterozygous M694V [19]. The presence of MEFV mutation probably upregulates the innate immune system with excessive release of interleukin 1  $\beta$  (IL-1 $\beta$ ) and promote an exaggerated response to the environmental triggers. This is supported by the fact that FMF patients and asymptomatic MEFV carriers have an increased subclinical baseline inflammation [20] which can predispose them to inflammatory diseases. IL-1 $\beta$  probably plays a major role, because it promotes effector function of neutrophils and macrophages, induces dendritic cell maturation, activates B cell, T helper CD4+ cell and favors Th17 polarization [21]. IL-1 $\beta$  can also promote caspase-1-dependent inflammatory cell death pyroptosis, were found to cause endothelial dysfunction, and may play a role in vasculitis development [4]. Environmental factors are also suspected to contribute or to trigger vasculitis development, like infectious diseases or treatment. Streptococcal infections have been reported to probably trigger events of vasculitis [19, 21-24]. In summary, genetic predispositions in the IL-1 pathway, including MEFV mutation, and environmental triggers probably favor vasculitis onset.

To conclude, FMF can be sometimes associated with systemic vasculitis. Diagnosis can be difficult in this setting, because of the similarities of FMF and vasculitis symptoms. Physicians should be aware about this association, and research vasculitis in case of a persistent episode of FMF over 72h, or with associated weight loss, renal impairment or any other atypical involvement, as suggested by expert recommendations [25].

## References

1. Livneh A, Langevitz P, Zemer D, Zaks N, Kees S, Lidar T, et al. Criteria for the diagnosis of familial Mediterranean fever. *Arthritis Rheum.* 1997 Oct; 40(10): 1879-85.
2. Yaçinkaya F, Ozen S, Ozçakar ZB, Aktay N, Cakar N, Düzova A, et al. A new set of criteria for the diagnosis of familial Mediterranean fever in childhood. *Rheumatol Oxf Engl.* 2009 Apr; 48(4): 395-8.
3. Giancane G, Ter Haar NM, Wulffraat N, Vastert SJ, Barron K, Hentgen V, et al. Evidence-based recommendations for genetic diagnosis of familial Mediterranean fever. *Ann Rheum Dis.* 2015 Apr; 74(4): 635-41.
4. Aksu K, Keser G. Coexistence of vasculitides with Familial Mediterranean Fever. *Rheumatol Int.* 2011 Oct; 31(10): 1263-74.
5. Akar S, Soysal O, Balci A, Solmaz D, Gerdan V, Onen F, et al. High prevalence of spondyloarthritis and ankylosing spondylitis among familial Mediterranean fever patients and their first-degree relatives: further evidence for the connection. *Arthritis Res Ther.* 2013; 15(1): R21.
6. Uslu N, Yüce A, Demir H, Saltik-Temizel IN, Usta Y, Yilmaz E, et al. The association of inflammatory bowel disease and Mediterranean fever gene (MEFV) mutations in Turkish children. *Dig Dis Sci.* 2010

- Dec; 55(12): 3488-94.
7. Abbara S, Grateau G, Ducharme-Bénard S, Saadoun D, Georgin-Lavialle S. Association of Vasculitis and Familial Mediterranean Fever. *Front Immunol*. 2019 Apr 12; 10: 763.
  8. Bayram Cengiz, Demircin Gülay, Erdoğan Özlem, Bülbül Mehmet, Çaltık Aysun, Akyüz Sare G. Prevalence of MEFV gene mutations and their clinical correlations in Turkish children with Henoch-Schönlein purpura. *Acta Paediatr*. 2011 Jan 13; 100(5): 745-9.
  9. Dogan CS, Akman S, Koyun M, Bilgen T, Comak E, Gokceoglu AU. Prevalence and significance of the MEFV gene mutations in childhood Henoch-Schönlein purpura without FMF symptoms. *Rheumatol Int*. 2013 Feb; 33(2): 377-80.
  10. Özçakar ZB, Yalçinkaya F, Çakar N, Acar B, Kasapçopur Ö, Ügüten D, et al. MEFV Mutations Modify the Clinical Presentation of Henoch-Schönlein Purpura. *J Rheumatol*. 2008 Dec 1; 35(12): 2427-9.
  11. Altug Umut, Ensari Cuneyt, Sayin Derya B., Ensari Arzu. MEFV gene mutations in Henoch-Schönlein purpura. *Int J Rheum Dis*. 2013 Aug 11; 16(3): 347-51.
  12. De Virgilio A, Greco A, Magliulo G, Gallo A, Ruoppolo G, Conte M, et al. Polyarteritis nodosa: A contemporary overview. *Autoimmun Rev*. 2016 Jun; 15(6): 564-70.
  13. Yalçinkaya F, Özçakar ZB, Kasapçopur Ö, Öztürk A, Akar N, Bakkaçoğlu A, et al. Prevalence of the MEFV Gene Mutations in Childhood Polyarteritis Nodosa. *J Pediatr*. 2007 Dec; 151(6): 675-8.
  14. Mahr A, Guillevin L, Poissonnet M, Aymé S. Prevalences of polyarteritis nodosa, microscopic polyangiitis, Wegener's granulomatosis, and Churg-Strauss syndrome in a French urban multiethnic population in 2000: A capture-recapture estimate. *Arthritis Rheum*. 2004; 51(1): 92-9.
  15. Hatemi G, Masatlioglu S, Gogus F, Ozdogan H. Necrotizing vasculitis associated with familial Mediterranean fever. *Am J Med*. 2004 Oct 1; 117(7): 516-9.
  16. Akar S, Goktay Y, Akinci B, Tekis D, Biberoglu K, Birlik M, et al. A case of familial Mediterranean fever and polyarteritis nodosa complicated by spontaneous perirenal and subcapsular hepatic hemorrhage requiring multiple arterial embolizations. *Rheumatol Int*. 2005 Jan 1; 25(1): 60-4.
  17. Lange-Sperandio B, Möhring K, Gutzler F, Mehls O. Variable expression of vasculitis in siblings with familial Mediterranean fever. *Pediatr Nephrol*. 2004 May 1; 19(5): 539-43.
  18. Girisgen I, Sonmez F, Koseoglu K, Erisen S, Yılmaz D. Polyarteritis nodosa and Henoch-Schönlein purpura nephritis in a child with familial Mediterranean fever: a case report. *Rheumatol Int*. 2012 Feb; 32(2): 529-33.
  19. Tekin M, Yalçinkaya F, Tumer N, Akar N, Misirlioğlu M, Çakar N. Clinical, laboratory and molecular characteristics of children with Familial Mediterranean Fever-associated vasculitis. *Acta Paediatr*. 2007 Jan 2; 89(2): 177-82.
  20. Lachmann HJ, Şengül B, Yavuzşen TU, Booth DR, Booth SE, Bybee A, et al. Clinical and subclinical inflammation in patients with familial Mediterranean fever and in heterozygous carriers of MEFV mutations. *Rheumatology*. 2006 Jun 1; 45(6): 746-50.
  21. Garlanda C, Dinarello CA, Mantovani A. The Interleukin-1 Family: Back to the Future. *Immunity*. 2013 Dec 12; 39(6): 1003-18.
  22. Sozeri B, Mir S, Ertan P, Kara OD, Sen S. Rapidly progressive glomerulonephritis in a child with Henoch-Schönlein Vasculitis and familial Mediterranean fever. *Pediatr Rheumatol Online J*. 2009 May 7; 7: 8.
  23. Ozen S, Ben-Chetrit E, Bakkaçoğlu A, Gur H, Tinaztepe K, Calguneri M, et al. Polyarteritis nodosa in patients with Familial Mediterranean Fever (FMF): A concomitant disease or a feature of FMF? *Semin Arthritis Rheum*. 2001 Feb 1; 30(4): 281-7.
  24. Bakkaçoğlu SA, Muzaç Ş, Akpek S, Söylemezoğlu O, Buyan N, Hasanoğlu E. Polyarteritis nodosa in a case of familial Mediterranean fever. *Pediatr Nephrol*. 2004 May 1; 19(5): 536-8.
  25. Ozen S, Demirkaya E, Erer B, Livneh A, Ben-Chetrit E, Giancane G, et al. EULAR recommendations for the management of familial Mediterranean fever: Table 1. *Ann Rheum Dis*. 2016 Apr; 75(4): 644-51.